

Useful Guide to Subpectoral Augmentation Mastopexy after Massive Weight Loss

SAAD MOHAMED SAAD IBRAHIEM, M.D., MRCS, EBOPRAS

The Department of Plastic Surgery, Reconstructive Surgery and Burn Management, Faculty of Medicine, Alexandria University

Abstract

Background: The extent of breast ptosis and deformity after massive weight loss is severe and the treatment of this problem is challenging. Recently, there has been a great deal of interest and several studies on augmentation mastopexy in this unique patient population due to the large number of patients who present after bariatric surgery.

Objective: This study aims to describe a useful guide for a single-stage augmentation mastopexy that combines the benefits of the submuscular plane with a superior dermoglandular flap for massive weight loss patients (MWLP) with grade 3 breast ptosis.

Methods: A retrospective cohort included 54 MWLP with grade 3 breast ptosis (nipple below the inframammary fold and lowest part of the breast) who underwent single-stage augmentation mastopexy between January 2016 and December 2020.

Results: The mean age of the patients was 32.4 years (range: 20 to 50 years), the mean current BMI was 26.6kg/m², and the mean follow-up time was 22 months (range: 13 to 56 months).

The patients reported outcome of the BREAST-Q scales were as follows: Physical well-being (89.3), sexual well-being (88.6), and psychosocial well-being (89.3).

The overall incidence of complications was of 18.52%. Mild wound healing problems in 6 patients. Reoperation in 4 cases (7.4%) due to implant malposition within 6 months post-operatively.

Conclusion: The study results showed that single stage augmentation mastopexy should be limited to patients with good breast symmetry and patients who desire rational volume augmentation.

Key Words: Augmentation-mastopexy – MWLP – Bottoming out – Breast implant – Subpectoral.

Ethical Committee: The present study follows the guidelines for good clinical practise and was approved by the Scientific Committee of the Faculty of Medicine, Alexandria

Correspondence to: Dr. Saad Mohamed Saad Ibrahim,
E-Mail: saad.saad@alexmed.edu.eg

University, under serial number 0305773. Written informed consent was obtained from all patients for the technique and photography studied.

Disclosure: No conflict of interest.

Introduction

One-stage augmentation mastopexy is a challenging but rewarding surgical technique. The single-stage procedure reduces surgical costs, required anesthesia, and recovery time.

The ideal candidate for augmentation mastopexy is a patient with adequate volume, dense breast parenchyma, mild to moderate ptosis, good skin quality, and a high breast footprint [1].

Unfortunately, the extent of ptosis and breast deformity following massive weight loss is extensive and patients aren't ideal candidates for single-stage mastopexy. In addition, the risk of complications is higher in patients with massive weight loss than in the general plastic surgery population [2].

Women who've lost a massive amount of weight typically present with the following breast deformities: a significant loss of breast volume, manifested by empty redundant breast due to a relative excess of skin compared to parenchymal volume, associated with a loss of skin elasticity; a medialized nipple position; and a pronounced axillary roll extending to or beyond the mid-axillary line, with loss of lateral curvature of the breast; and a loose and lateral inframammary fold [3].

Mastopexy alone is often disappointing because the upper pole of the breast is lacking volume. Insertion of a breast implant is essential to restore an esthetically pleasing breast. Most patients want surgery in one step to save cost and recovery time [4].

Objective:

The aim of this study is to describe a reliable single-stage augmentation mastopexy that combines the advantages of the submuscular plane with

a superior dermoglandular flap for massive weight loss patients (MWLP) with grade 3 breast ptosis.

Patients and Methods

This is a retrospective cohort of 54 MWL women with grade 3 breast ptosis (nipple located below the inframammary fold and the lowest part of the breast) who underwent single-stage augmentation mastopexy between January 2016 and December 2020.

The present study follows the guidelines for good clinical practise and was approved by the Scientific Committee of the Faculty of Medicine, Alexandria University, under serial number 0305773. Written informed consent was obtained from all patients for the technique and photography studied.

Inclusion criteria were female MWL with Regnault (5) grade 3 breast ptosis (the NAC is >4cm below the IMF, at the dependent part of the lower pole of the breast), aged >18 years, and BMI <30kg/m².

Exclusion criteria were BMI >30kg/m², active smokers, and patients with unrealistic expectations. (These patients are better treated with the 2-stage technique).

The following surgical guidelines were used in the study:

- Elevation of the nipple 1-2cm above the the midline of the inframammary fold, since it is usually displaced downward after massive weight loss.
- The vertical scar should be 5-6cm long.
- No undermining of the breast parenchyma reduce the risk of wound healing problems.
- Creating a subpectoral pocket increases the stability of the pocket.
- Selecting implants that are high profile but small to moderate size. (<330cc)

- Firm fixation of the new IMF with nonabsorbable sutures.

Preoperative examination:

A detailed history included history of weight loss, the preoperative and the presenting body mass index (BMI), full nutritional evaluation, the medical comorbidities and history of previous breast surgery.

Pre-operative assessment:

Standard breast measurements included nipple to sternal notch distance (N-SN), nipple to inframammary fold distance (N-IMF), and breast base to determine the degree of breast ptosis. The examination included condition of the skin, volume of the subcutaneous fat, and the amount of parenchyma in the upper pole of the breast.

Marking of the cardinal landmarks: (In standing position).



video1-marking_W
VgFGGMi.mp4

Video (1): Marking.

We follow the Ramirez [6] design for skin excision in all study patients, which ends with a small T-scar that is smaller than the T-scar of the well-known Wise pattern skin excision.

Three reference lines were marked: The midline, the breast meridian, and the IMF. Three important breast dimensions were marked: The N- ST distance, the N-IMF distance, and the base of the breast; this was helpful in determining the size of the implant. Fig. (1).

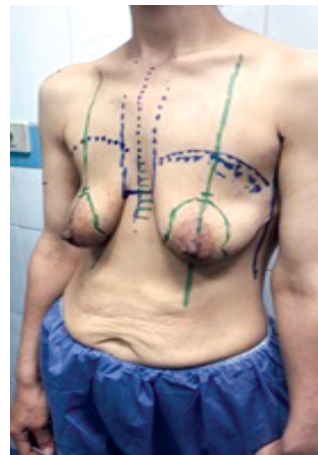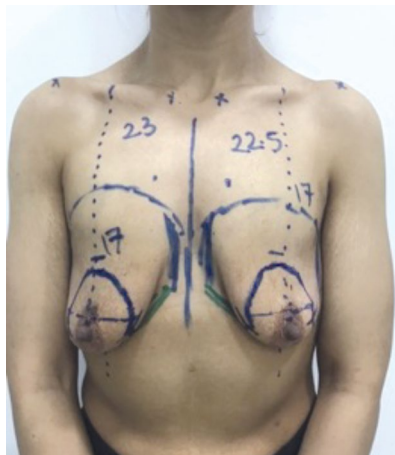


Fig. (1): Preoperative markings. The sternal notch, midline, IMF, upper breast border, and breast meridians (dashed lines) were marked. The new nipple position was marked 1-2 above the current IMF. The vertical skin pattern for mastopexy was marked with a displacement technique preoperatively.

The new nipple position was marked 1-2cm above the presenting infra-mammary line in the midline of the breast, with the areola window was at the level of the mid-arm.

A vertical ellipse was marked by rotating the breast medially and laterally as described by Hall-Findlay [7]. The vertical limb of the mastopexy pattern was marked at 5-6cm, the vertical limb was measured from the base of the nipple areola complex. (The shortening of the vertical scar counteracts its expected postoperative stretch due to the inherited nature of overstretched skin in MWLP).

The planned position of the upper pole of the implant was marked on the chest wall to allow intraoperative assessment and adjustment.

Position:

Patients were in the supine position with head tilted to 45 degrees and arms abducted. After induction of general anesthesia, disinfection and draping were started.

Operative technique:

The cardinal lines of the breast were infiltrated with tumescent infiltration consisting of one liter of saline, 1 ml of epinephrine, and 20ml of lidocaine 1%. 100-250ml of the tumescent fluid was infiltrated into the incision lines and the deepithelialization site.

A suitable cookie cutter was used to delineate the the new areola. deepithelialization was carried out to create a superior dermoglandular NAC pedicle.

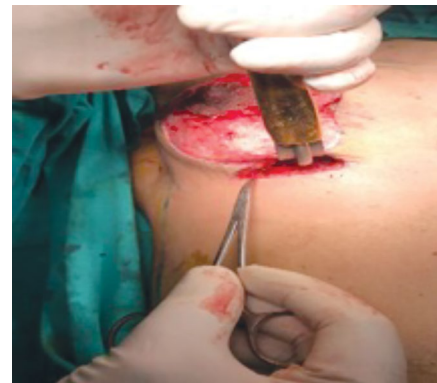Only the skin was removed at the vertical and transverse ellipses, and the breast parenchyma was incised to the level of the pectoralis major muscle.

The lower pectoral muscle fibers were identified with blunt dissection, the subpectoral plane was entered, and both blunt and bipolar cauterization was used to develop an appropriate implant pocket. The medial dissection was performed carefully to avoid injury to the second and third internal mammary arteries. The inferior internal quadrant of the musculoaponeurotic attachment of the pectoralis muscle was released to allow natural positioning of the implant.



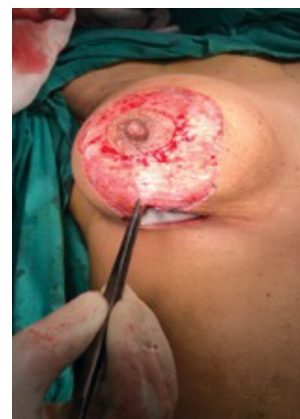video3-subpectoral-pocket_CGG1upSt.i

Video (3): (Subpectoral Pocket).



video4-implant-volume-confirmation-u

Video (4): Volume Confirmation Using sizers.

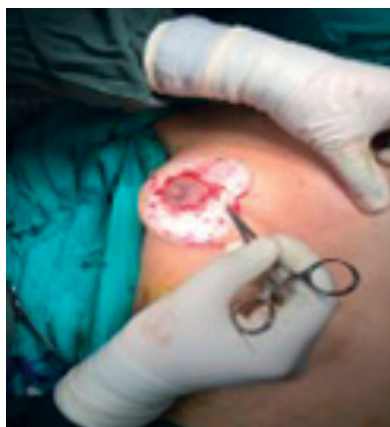

Sizers were used to confirm the implant volume.



video2-dermal-excision_tW1FOzSt.mp4

Video (2): Dermal Excision.



Hemostasis was checked, drainage was placed, and the implant was placed in the subpectoral pocket.

Staples were used to temporarily close the skin.

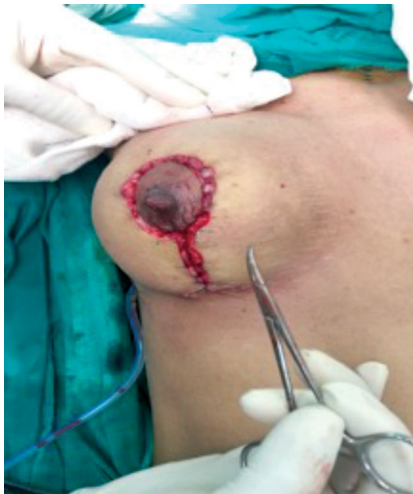At the end of the procedure, shape, fullness and symmetry of both breasts were checked, where fine adjustments may be done through a small skin excision to place the nipple in the center of the breast.

Areolar wound closure was performed using 4/0 Vicryl followed by closure of breast pillars with interrupted deep parenchymal bites of 2-0 Vicryl. To fix the new IMF, permanent (2/0 prolene) deep parenchymal suture was used on the costal periosteum at the level of the 6 ribs (correspondent with silicone implant lower border to prevent the migration of the implant inferiorly) along the transverse incision. Skin closure was performed with 3-0 Vicryl and 4-0 Monocryl for subdermal and subcuticular closure.



video5-closure_vIU dJfpx.mp4

Video (5): Wound Closure.



Steri-strips were used to apply the dressings, and a surgical bra was applied.

Postoperative care: Viability of nipple areola complex was checked, and follow-up visits were arranged twice weekly. A compression medical bra was worn for six weeks, and the patient was advised to wear a push-up sport bra for another 6 months.

Three parameters were used to compare the outcome of the technique; (1) N-IMF length, 6 and 12 months postoperatively to detect the stretching of the vertical scar, (2) The complication rate whether minor complications in the form of hematoma, seroma, infection, and wound healing problems or major complications in the form of nipple loss, major wound dehiscence leading to implant exposure, and reoperation, and (3) The BREAST-Q was used to measure patient satisfaction.

Results

The retrospective cohort included 54 women with grade 3 breast ptosis who underwent single-stage augmentation mastopexy between 2016 and 2020. Patients ages ranged from 20-50 years with the mean age was 32.4 years. There were 26 (48.15%) patients in the age group 20-30 years, 18 patients (33.33%) in the age group 30-40 years, while 10 patients (18.52%) were in the age group 40-50 years.

Patients BMI ranged from 26.6kg/m² 29.7kg/m², while 20 patients (37.03%) had ideal body weight (The BMI was 19-25kg/m²), 34 patients (62.97%) failed to reach the ideal body weight. The average morbid BMI was 44.9 kg/m², and the average weight loss after bariatric surgery was 49 kg. Seven patients (12.96%) had high delta BMI (change from maximum BMI to current operating BMI), all have severe breast ptosis with N-ST distance greater than 35cm. Forty-four patients (81.48%) underwent lap-sleeve gastrectomy for weight loss, while lap-bowel bypass was the method of weight loss in 10 patients (18.52%).

The follow-up ranged from 13 to 56 months, with a median time of 22 months.

The average operation time was 90 minutes, which could be considered a quick operative time for post weight loss augmentation mastopexy, because an assistant did some of the suturing, while the author dissected the contralateral breast.

No glandular resection was performed; only the skin was removed.

All patients had round cohesive silicone gel implants with microtexture and medium to high profile, depending on the patient's preference, with some patients rejecting the prominent, fully protruding breast mound for cultural reasons.

All were placed in the subpectoral plane. The volume of the implants ranged from 185 to 320mL. the average implant volume of the right breast was 265ml, and that of the left side was 272ml.

The average N- ST distance of the right breast was 28.3cm (range 26 to 38cm) and that of the left breast was 27.9cm. (Range between 25 and 37cm).

The mean NAC elevation of the right breast at 12 months postoperatively was 8.7 cm (range: 5-15cm). Mean NAC elevation of the left breast at 12 months postoperatively was 8 cm (range: 4-17cm).

The average N-IMF length of the right breast preoperatively was 8.4cm and that of the left breast was 8.07cm. Originally, the NAC was supposed to be about 4.5cm in diameter, but the final size is usually expanded to 5-6cm in diameter because the skin is inherently weaker in MWLP.

The immediate intraoperative N-IMF length was maintained between 5-6cm. Measurement of N-IMF distance 12 months postoperatively showed the following results: 34 patients (62.96%) showed an increase in N-IMF distance (0-1cm). 18 patients (33.33%) showed moderate increase (more than 1cm-less than 3cm) of N-IMF distance; which does not affect the satisfaction rate of most patients. Four patients (7.4%) showed significant stretching of the vertical scar (>3cm), which required reoperation.

Ten patients (18.52%) suffered early complication in the form of minor wound healing problems, all of which healed conservatively. No hematoma, no seroma and no serious implant exposure noted in the study.

Late complications involved reoperation in 4 cases (7.4%) due to double-bubble because of significant stretching of the vertical scar of the mastopexy. Moderate stretching of the vertical scar didn't result in bottoming, so revision surgery wasn't necessary.

No capsular contracture has occurred in the study to date. Also none of the studies patients presented muscle animation because MWLP are usually have muscle wasting due to possible nutritional deficiency.

Patient-reported outcomes:

Patients outcome data were collected from the clinical examination in the follow-up visits, and a WhatsApp interview with them (Breast-Q questionnaire was sent to the patients as a link, which was prepared using Office 365 application forms). Then, the patients' responses were sent directly and separately to the application to be collected in the excel sheet form, where the statistical data were calculated. Overall, 92.59% of patients (n=50) reported that they were "satisfied," and 7.41% of patients (n=4) were "dissatisfied" due to poor esthetic outcomes.

Table (1): Shows the demographic data of the studied patients.

Total number of studied patients	54
<i>Age (years):</i>	
Minimum	20
Maximum	50
Mean	32.4
<i>Age Groups:</i>	
20-30	26 (48.15%)
31-40	18 (33.33%)
41-50	10 (18.52%)
<i>Weight (kg):</i>	
Minimum	43
Maximum	86
Mean	67.24
<i>Weight Loss (kg):</i>	
Minimum	37
Maximum	70
Mean	49
<i>Morbid BMI:</i>	
Minimum	39.7
Maximum	54.7
Mean	44.9
<i>Operating BMI:</i>	
Minimum	20.4
Maximum	29.7
Mean	26.6
<i>BMI Group:</i>	
<19	0
19-25	20 (37.03%)
26-30	34 (62.97%)
<i>Follow-up (months):</i>	
Minimum	13
Maximum	56
Mean	22

Table (2): Presents the volume of breast implant in the studied group.

Implant size (ml)	Right side	Number (%) of patients	Left side	Number (%) of patients
185		4 (7.4%)	0	
195		6 (11.1%)	6 (11.1%)	
225		4 (7.4%)	6 (11.1%)	
250		2 (3.7%)	8 (14.8%)	
265		16 (29.6%)	14 (25.9%)	
285		4 (7.4%)	4 (7.4%)	
300		6 (11.1%)	2 (3.7%)	
320		12 (22.2%)	14 (25.9%)	

Table (3): Showed the pre-operative and post-operative breast measurements.

Breast measurements (cm)	Pre-operative		Post-operative	
	Right breast	Left breast	Right breast	Right breast
<i>ST-N:</i>				
Minimum	26	25	21	20
Maximum	38	37	23	21
Mean	28.3	27.9	21.3	20.8
<i>NAC elevation:</i>				
Minimum			5	4
Maximum			15	17
Mean			8.7	8
<i>N-IMF:</i>				
			N-IMF stretch	
Minimum	5	4	0-1cm	34 (62.96%)
Maximum	13	14	1-3cm	18 (33.33%)
Mean	8.4	8.07	> 3 cm	4 (7.4%)

Table (4): Represented the Breast-Q result of the study.

The parameter	The result (out of 100)
The breast before augmentation mastopexy	29.6
The breast 12 months after augmentation mastopexy	90.1
Nipples	85.6
Pre-operative information during pre-operative consultation	90.9
Surgeon performance and preoperative information	91.1
Medical staff assistance and behaving	89.1
Office staff assistance and behaving	83.1
Physical activities	89.3
Intimate life	88.6
Psychosocial well-being	89.3

Figs. (2-3): Show the clinical outcome of 2 cases in the study.

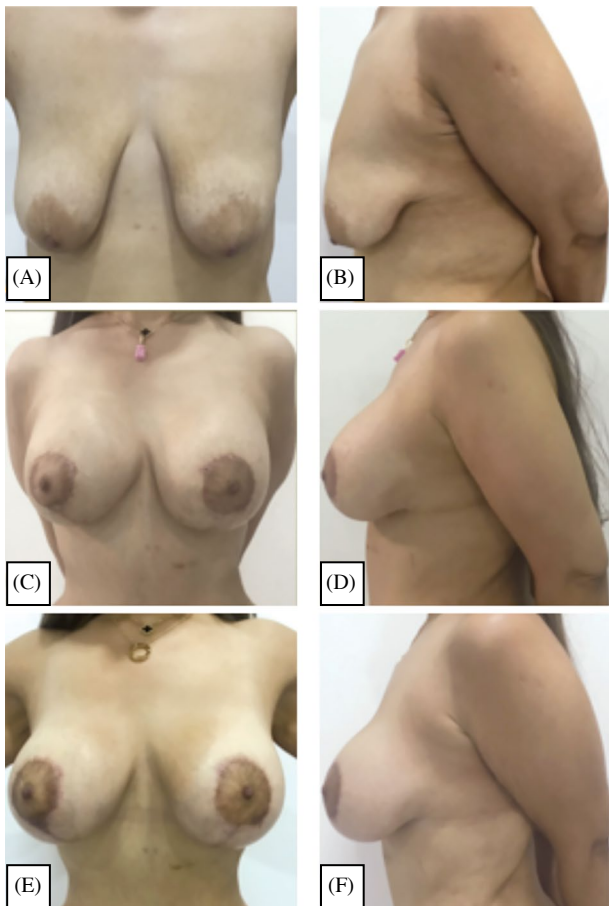


Fig. (2): Case (1): 36 years old female with grade 3 breast ptosis who lost 42 Kg after lab sleeve gastrectomy.

Photos (A & B): Show the pre-operative measure of Right N-ST was 30 cm and 31 cm on the left.

Augmentation mastopexy was done using 320cc round, semismooth Sebbin silicone implants placed at the subpectoral plane.

Photos (C & D): Show the postoperative results at 6 months and photos E & F show the postoperative results at 12 months with the nipple elevation was 9 cm on the right and 10 cm on the left.

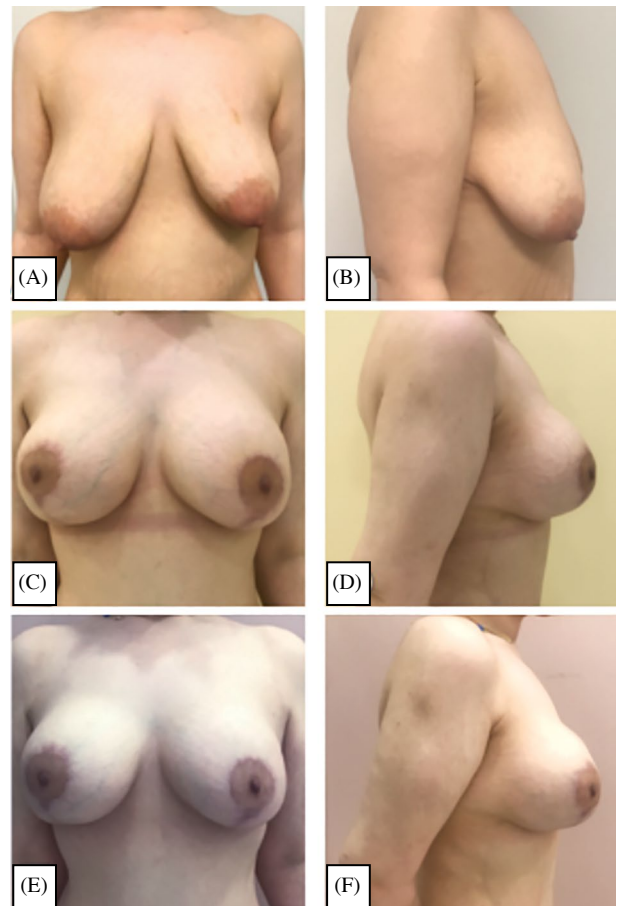


Fig. (3): Case (2): 36 years old female with grade 3 breast ptosis with asymmetry following loss of 41 Kg after lab sleeve gastrectomy.

(A and B): Preoperative photos show right N-ST was 28 cm and 25 cm on the left.

(C and D): Postoperative result at 6 months, and E and F postoperative results at 12 months show Nipple elevation was 8 cm on the right and 5 cm on the left. After augmentation mastopexy with round, semismooth Sebbin silicone implants; the right side was 285 cc and left 320cc placed at the subpectoral plane.

Discussion

The goals of single-stage augmentation mastopexy are to elevate the nipple by resection of excess skin and to increase breast volume by placement of an appropriate breast implant. The procedure is associated with complication risks in MWLP ranging from minor wound healing problems to poor cosmetic outcome requiring revision [2].

Despite the complication risks, high patient satisfaction can be achieved if the procedure is properly planned and performed. Many plastic surgeons have described useful clinical tips to reduce the incidence of complications and overcome the unfavorable surgical outcomes of single-stage augmentation mastopexy in MWLP. Rubin et al., [8] described a technique of dermal suspension and parenchymatous reshaping of the breast by autoaugmentation from lateral chest wall tissue. Unfortunately, this technique has two major disadvantages: Extensive intraoperative adjustment (time-consuming) and long scars. Nghiem et al., [9] recommend not releasing the pectoralis to prevent long-term bottoming out in MWLP with poor skin quality. Various mesh materials and dermal matrices have been tried for additional support during augmentation mastopexy. The disadvantages of these materials include the added cost of the product, increased operative time, and potential risk of extrusion or infection until revascularization [10,11].

In the present study, a well-established plastic surgery technique "single-stage augmentation mastopexy" was not investigated, but the study provided some useful clinical tips to elevate the nipple more than 4cm, as described by Beale et al., [12] in single-stage augmentation mastopexy, without significant complications in postbariatric patients suffering from severe breast deformity.

Because of the loose connection between the breast parenchyma and the pectoralis muscle in MWLP, the author was able to easily wrap the breast parenchyma over the subpectoral silicone breast implant. In addition, the muscle atrophy in MWLP prevents significant muscle animation. No lower pole parenchymal resection was performed to push the implant further up and prevent significant bottoming.

Small to medium sized, moderate to high profile breast implants were placed in the subpectoral pocket to reduce the additional volume and minimize the risk of stretching the vertical scar: The cause of secondary bottoming. Theoretically high-profile implants result in greater projection of the NAC, but also it causes greater distance from the NAC to the breast support base, which increases the force vector and may favor late ptosis. Moderate profile microtextured implants were usually used in the study, and for patients who asked for large volume

augmentation, high profile implants with moderate volume were used, because large volume implants with poor elasticity of skin in MWLP will lead to definite ptosis. Lee et al., [13] retrospectively compared the use of smooth and microtextured breast implants in 266 patients who underwent breast augmentation surgery and found that there was no significant difference between the two groups in terms of complication and reoperation rates. In the group with the smooth implants, 14.4% of patients experienced complications, compared to only 8.2% in the group with the microtextured implants.

There is no doubt that skin changes which is related to age have a direct influence on the result. 81.48% of the studied patients were in the age group 20-40 years, this reflected the good results in this age group.

Long T-shaped scars were avoided. The musculoaponeurotic attachment of the pectoralis muscle was partially released along the inner quadrant of the IMF to prevent upward and lateral migration of the implant. This method is consistent with Coombs et al., [14], who advocate release of the inferior pectoralis muscle, but contrasts with the technique described by Nghiem et al., [9].

Complication rate:

The complication rate of the present study was low (18.52%), which compares favorably with other published studies on single-stage augmentation mastopexy documenting an overall complication rate of 13%-36% [15,16].

Follow-up showed that the vertical scar stretched by 1-3cm. This change was noted mainly in the first 6 months after surgery. This finding is also consistent with Coombs et al., [13] who found that MWL patients are at increased risk for early postoperative ptosis or implant malposition during the first 6 postoperative periods.

Revision rate:

A review of the literature found that reoperation rates for single-stage augmentation mastopexy ranged from 6.5% to 25.8% [17,18]. These numbers compare to a reoperation rate of 15.4% to 28% for primary augmentation alone [19,20]. Calobrace et al., [21] demonstrated that the reoperation rate was not significantly higher than the additive rate for performing the two procedures independently; it was 10.2% for mastopexy alone, comparable to the augmentation mastopexy of 13.3%. Spear [22] argued that the operative revision rate of a single-stage augmentation mastopexy is much lower than the sum of the two procedures.

The present study showed a revision rate of (7.4%), which compares favorably with the rates reported in the literature. Four patients required reoperation because of double-bubble deformity. The

revision rate was noted in patients had the following characteristics preoperatively: N-IMF distance was greater than 8cm, N-ST distance >35cm and patients with high delta BMI (change from maximum BMI to current operating BMI).

Xue et al., [16] found that revision was often performed in patients with massive weight loss because of the desire to change implant size.

Coombs et al., [12] found that there were two predictors of early postoperative ptosis: The age factor due to age-related changes in skin elasticity and a higher BMI at the time of surgery after massive weight loss.

The author can add three possible predictors of early postoperative ptosis: N-IMF distance >8cm, N-ST distance >35cm and patients who desire large implants.

The strength of the study is the longer follow-up period (up to 56 months), which showed acceptable durable results in terms of upper pole fullness and a lower incidence of bottoming out, as evidenced by a low reoperation rate (7.4%) and high patient satisfaction with their results.

Conclusion:

One-stage augmentation mastopexy is a safe procedure with acceptable results, and the complication rate is comparable to that of two-stage techniques. The technique could be predictable and feasible if adequate consideration is given to planning and surgical technique.

Preoperative planning should include adequate elevation of the NAC, and MWLP with grade 3 breast ptosis should have realistic expectations of the technique.

The present study does not propose a new technique, but it extends the indication for single-stage augmentation mastopexy to MWLP that have grade 3 ptosis with a N-IMF distance of no more than 8cm.

Limited manipulation of the breast parenchyma with the skin decreases the incidence of wound healing problems.

The use of a submuscular pocket provides additional coverage of the breast implant in MWLP with low skin turgor and provides a more natural breast appearance.

The technique should be avoided in the following type of patients, and staged augmentation mastopexy should be performed in patients with an N-IMF distance greater than 8cm, ST-N distance greater than 35 cm, high delta BMI, in patients with significant asymmetry where symmetry should be

achieved in the first phase and then symmetrical augmentation should be performed in a second phase, and in patients who desire large volume augmentation.

References

- 1- Calobrace M.B. and Gabriel A.: Mastopexy with Autoaugmentation and Fat Transfer. *Clin Plast Surg.*, 48 (1): 17-32. doi:10.1016/j.cps.2020.09.008, 2021.
- 2- Constantine R.S., Davis K.E. and Kenkel J.M.: The effect of massive weight loss status, amount of weight loss, and method of weight loss on body contouring outcomes. *Aesthet Surg. J.*, 34 (4): 578-583. doi:10.1177/1090820X14528208, 2014.
- 3- Beidas O.E. and Rubin J.P.: Breast Reshaping After Massive Weight Loss. *Clin. Plast. Surg.*, 46 (1): 71-76. doi:10.1016/j.cps.2018.08.009, 2019.
- 4- Lang Stümpfle R., Piccinini P.S., Pereira-Lima L.F. and Valiati A.A.: Muscle-Splitting Augmentation-Mastopexy: Implant Protection With an Inferior Dermoglandular Flap. *Ann. Plast. Surg.*, 82 (2): 137-144. doi:10.1097/SAP.0000000000001689, 2019.
- 5- Regnault P.: Breast ptosis. Definition and treatment. *Clin. Plast. Surg.*, 3 (2): 193-203, 1976.
- 6- Ramirez O.M.: Reduction mammoplasty with the "owl" incision and no undermining. *Plast. Reconstr. Surg.*, 109 (2): 512-524. <https://doi.org/10.1097/00006534-200202000-00016>, 2002.
- 7- Hall-Findlay E.J.: Vertical breast reduction. *Semin Plast. Surg.*, 18 (3): 211-224. doi:10.1055/s-2004-831908, 2004.
- 8- Rubin J.P., Gusenoff J.A. and Coon D.: Dermal suspension and parenchymal reshaping mastopexy after massive weight loss: statistical analysis with concomitant procedures from a prospective registry. *Plast. Reconstr. Surg.*, 123 (3): 782-789. doi:10.1097/PRS.0b013e31819ba1a8, 2009.
- 9- Nghiem B.T., Koenig W. and Amalfi A.N.: Augmentation Mastopexy: Challenging Dogma to Produce Long-Term Aesthetic Results. *Advances in Cosmetic Surgery*, (4): 161-173. <https://doi.org/10.1016/j.yacs.2021.02.005>, 2021.
- 10- Nava M., Rancati A., Rocco N., Catanuto G. and Irigo M.: Improving aesthetic outcomes in mastopexy with the "autoprosthesi" technique. *Gland Surg.*, 6 (2): 141-147. doi:10.21037/g.s.2017.03.05, 2017.
- 11- Kirwan L., Wazir U. and Mokbel K.: Breast Auto-Augmentation: A Versatile Method of Breast Rehabilitation-A Retrospective Series of 107 Procedures. *Arch. Plast. Surg.*, 42 (4): 438-445. doi:10.5999/aps.2015.42.4.438, 2015.
- 12- Beale E.W., Ramanadham S., Harrison B., Rasko Y., Armijo B. and Rohrich R.J.: Achieving predictability in augmentation mastopexy. *Plast. Reconstr. Surg.*, 133 (3): 284e-292e. doi:10.1097/PRS.000000000000079, 2014.

- 13- Lee J.H., Jang J.H. and Min K.H.: A Comparison of Smooth and Microtextured Breast Implants in Breast Augmentation: A Retrospective Study. *Arch. Plast. Surg.*, 50 (2): 160-165. Published 2023 Mar, 28. doi:10.1055/s-0042-1760405, 2023.
- 13- Coombs D.M., Srivastava U., Amar D., Rubin J.P. and Gusenoff J.A.: The Challenges of Augmentation Mastopexy in the Massive Weight Loss Patient: Technical Considerations. *Plast. Reconstr. Surg.*, 139 (5): 1090-1099. doi:10.1097/PRS.0000000000003294, 2017.
- 14- Stevens W.G., Macias L.H., Spring M., Stoker D.A., Chacón C.O. and Eberlin S.A.: One-Stage Augmentation Mastopexy: A Review of 1192 Simultaneous Breast Augmentation and Mastopexy Procedures in 615 Consecutive Patients. *Aesthet. Surg. J.*, 34 (5): 723-732. doi:10.1177/1090820X14531434, 2014.
- 15- Artz J.D., Tessler O., Clark S., Patel S., Torabi R. and Moses M.: Can It Be Safe and Aesthetic? An Eight-year Retrospective Review of Mastopexy with Concurrent Breast Augmentation. *Plast Reconstr Surg Glob Open.*, 7 (6): e2272. Published 2019 Jun. 12. doi:10.1097/GOX.0000000000002272, 2019.
- 16- Lee M.R., Unger J.G. and Adams W.P. Jr.: The tissue-based triad: A process approach to augmentation mastopexy. *Plast. Reconstr. Surg.*, 134 (2): 215-225. doi:10.1097/PRS.000000000000387, 2014.
- 17- Xue A.S., Dayan E. and Rohrich R.J.: Achieving Predictability in Augmentation Mastopexy: An Update. *Plast Reconstr Surg. Glob Open.*, 8 (9): e2784. Published 2020 Sep. 21. doi:10.1097/GOX.0000000000002784, 2020.
- 18- Swanson E.: All Seasons Vertical Augmentation Mastopexy: A Simple Algorithm, Clinical Experience, and Patient-reported Outcomes. *Plast. Reconstr. Surg. Glob. Open.*, 4 (12): e1170. Published 2016 Dec. 27. doi:10.1097/GOX.0000000000001170, 2016.
- 19- Cunningham B.: The Mentor Core Study on Silicone MemoryGel Breast Implants. *Plast. Reconstr. Surg.*, 120 (7 Suppl 1): 19S-29S. doi:10.1097/01.prs.0000286574.88752.04, 2007.
- 20- Codner M.A., Mejia J.D., Locke M.B., et al.: A 15-year experience with primary breast augmentation. *Plast. Reconstr. Surg.*, 127 (3): 1300-1310. doi:10.1097/PRS.0b013e-318205f41b, 2011.
- 21- Calobrace M.B., Herdt D.R. and Cothron K.J.: Simultaneous augmentation/mastopexy: A retrospective 5-year review of 332 consecutive cases. *Plast. Reconstr. Surg.*, 131 (1): 145-156. doi:10.1097/PRS.0b013e318272bf86, 2013.
- 22- Spear S.L., Dayan J.H. and Clemens M.W.: Augmentation mastopexy. *Clin. Plast. Surg.*, 36 (1): 105-117. doi:10.1016/j.cps.2008.08.006, 2009.