

Combined Endoscopic Latissimus Dorsi Flap with Fat Graft versus Extended Latissimus Dorsi Flap for Breast Reconstruction

YASMIN T. BARAKAT, M.B.B.Ch.; AHMED M. ELBADAWY, M.D.; AHMED M. ABDELSALAM, M.D.; DALIA M. GALAL, M.D. and MOHAMED S. BADAWEY, M.D.

The Department of Plastic, Burn and Maxillofacial Surgery, Faculty of Medicine, Ain Shams University

ABSTRACT

Background: Various breast reconstruction techniques after mastectomy have been developed over the last few years based on the idea of volume replacement, either by autologous flaps, such as Latissimus dorsi (LD) flap or device-based techniques, such as implants. Combined Endoscopic LD flap with fat graft is an advanced technique that enhances the muscle volume and lower the postoperative complications.

Objectives: Comparison between combined Endoscopic LD Flap with fat graft versus extended LD Flap for breast reconstruction in breast cancer patients regarding the aesthetic outcome, and patient satisfaction on long term results.

Patients and Methods: There were 40 female patients with early invasive breast carcinoma, including stages I, II, and III A, in accordance with the American Joint Committee on Cancer (AJCC) staging system (1) in this comparative analysis. Twenty patients each performed skin sparing mastectomy and immediate reconstruction using the conventional extended (LD) flap technique and the endoscopic (LD) flap with fat graft technique. Volume differences between the two studied groups that were evaluated before the surgery and six months after surgery were noted. Additionally, the donor site scar and patient satisfaction with the reconstructed breast were compared.

Results: When compared to the conventional group, there was a substantial average volume decrease of the reconstructed breast in the endoscopic group (38.1 versus 18.1 percent, $p=0.001$). Despite the fact, the endoscopic group's operation took longer time than the conventional group's (203 vs 151 min, $p=0.017$), which is considered a disadvantage, donor site scar and postoperative seroma was better in the endoscopic group.

Conclusion: Endoscopic LD muscle flap with fat graft is better than Extended Latissimus dorsi muscle flap for breast reconstruction regarding overall patient satisfaction and post operative donor site complications. Therefore, endoscopic LD muscle flap with fat graft could represent an alternative technique to Extended LD muscle flap in cases of early invasive breast cancers, including stages I, II, and IIIA, as specified by American Joint Committee on Cancer (AJCC) staging system (1).

Key Words: Breast cancers – Skin sparing mastectomy – Reconstruction – Latissimus Dorsi flap – Fat graft.

Disclosure: No conflict of interest.

INTRODUCTION

In Egypt, breast cancer ranks the highest incidence, representing 32.4% of all cancers among women [2].

Oncoplastic procedures, which are needed for meticulous preoperative planning with a multidisciplinary team including radiologists, pathologists, and surgical oncologists, are used in the therapy of breast cancers in the current day [3]. A full-scale evaluation of the breast to determine the paradigmatic surgical technique is mandatory with high attention to scar placement [4].

Today, a variety of therapeutic options are provided to women with newly diagnosed breast cancer in a multidisciplinary environment [5]. Based on the cancer's dimension in relation to the patient's breast size or their decision to have a mastectomy or breast preservation, breast carcinoma surgeries is no longer a two-operation specialty; instead, the primary goal is instant breast restoration [6].

The Latissimus Dorsi (LD) flap has been a long-term standard for breast reconstruction [7]. It is a solid option for women with small to medium-sized breasts because there is usually not much fat on this part of the back [8]. In most cases, a breast prosthetic implant must be placed under the flap to attain better shape and projection with more enhanced size [9].

Despite its widespread use, two limitations of the Extended LD muscle flap for reconstructing the breast are the conspicuous slightly remaining donor site scar and the modest volume of the muscle flap, which often necessitates breast implant augmentation to provide the best cosmetic outcome [10,11].

Endoscopic (LD) muscle flap with fat graft provides a secure method for autologous breast

rebuilding [8]. It has the benefit of protecting against the problems of implant-based breast rebuilding, making it a good substitute for other autologous pedicled flaps in breast rebuilding [12].

PATIENTS AND METHODS

The Plastic & Reconstructive Surgery Department, Faculty of Medicine, Ain Shams University performed this comparative research from December 2020 to December 2021. The Research Ethics Committee of the Faculty of Medicine at Ain Shams University authorized this work.

Ethical considerations: All participants gave their consent. The research ethics committee of the Faculty of Medicine at Ain Shams University authorized this work.

Inclusion criteria: In this study, adult females (25-55) years, BMI (18.5-30), with confirmed early invasive breast cancer with no skin involvement or distant metastasis; stages I, II, and IIIA, regarding to American Joint Committee on Cancer (AJCC) staging system (1) were included. Also, we included patients with Nipple-Areola Complex invasion by cancer cells, breast size ranging from 300cc to 700cc, determined by preoperative volumetric mammography.

Exclusion criteria: Female patients less than 25 or more than 55 years, and BMI ($<18.5\text{Kg/m}^2$), not suitable for fat transfer, or ($>30\text{Kg/m}^2$), obese patients with large breasts not suitable for LD muscle flap reconstruction, were not included in the study. Locally advanced breast cancer: stage IIIB and stage IV were also excluded. Also, we excluded breast size less than 300cc and more than 700cc.

Preoperative examination:

A thorough history of each patient was taken, including information on their age, family history, and usage of hormonal intrauterine devices or oral contraceptives. The radiologic studies included volumetric mammography, ultrasonography, a metastatic radiologic work-up, and a thorough clinical evaluation of both breasts. For the purpose of confirming the diagnosis, all patients underwent fine-needle aspiration cytology (FNAC) and/or true-cut biopsy.

Surgical intervention:

All procedures were done under general anesthesia. The patients' general status and vital signs were documented. Written consent was taken from the patient regarding surgery and intraoperative photography.

Participants in the current study were divided into two groups by a simple randomization method, in which a block size of 4 was chosen and 10 blocks were needed to assign all 40 patients. Each block contained 2 patients each of Group I and Group II [13].

Group I: Skin sparing mastectomy and immediate reconstruction with Extended LD Muscle Flap were used to treat 20 patients with early invasive breast cancers.

Group II: Skin sparing mastectomy and immediate reconstruction with Endoscopic LD muscle flap and fat graft were used to treat 20 patients with early invasive breast cancers.

Pre-operative marking:

For group I and Group II: For LD flap, the patient was in the standing posture for preoperative flap design, and the angle of the inferior border of the scapula was marked (Figs. 1,2).

Surgical technique:

Skin sparing mastectomy:

Group I and Group II:

The patient was put in a supine position while being given general anesthesia, and a skin incision was made. Then, de-epithelization of the skin between the two round block incisions were done except for the dermal flap, which depends on the subdermal blood supply [14] which was designed to be the future areola (Fig. 3).

The entire breast tissue with the overlying nipple and areola were excised and separated from their attachment to the skin (Fig. 4).

Latissimus Dorsi muscle flap harvesting:

Group I: Extended LD muscle flap harvest (Figs. 5,6):

The LD muscle's superior and posterior boundaries were visible when the flaps were raised. The LD's posterior edge was then raised and pulled backwards, revealing the serratus anterior muscle underneath. Blunt dissection widened the gap between the LD and serratus anterior muscles. The latissimus muscle was then released from its posterior edge. Then, dissection was continued distally and inferiorly to free out and to mobilize the muscle to the operative defect.

Group II: Endoscopic LD muscle flap harvest (Fig. 7):

Dissection was done by the diathermy through the subdermal layer and the subcutaneous fatty layer until the anterior border of the LD muscle

was reached. The anterior border of the LD muscle was dissected and identified as in an open procedure when the LD muscle could be seen through the incision. In order to implant an endoscopic illuminated breast retractor and energy device (long pen diathermy), the surgical assistant first lifted the surrounding skin using a surgical minor wound retractor (Model nm-di-786813, Sculpo endoscopic retractor with a channel for endoscopes, New Med Supplies, Pakistan), with an integrated 10mm camera (Figs. 8,9,10).

Transposition of the flap:

Group I and Group II:

Over the pectoralis muscle, a subcutaneous tunnel was made, through which the distal end of the LD flap paddle was inserted. Once the flap had been inserted without tension into the operating defect after passing through the tunnel.

Donor site: We treated the donor site incision with sealed vacuum drainage devices to prevent seromas postoperatively and closed the incision using the two-layer closure technique.

Breast reconstruction phase:

The patient was put again in supine posture and the volume of the muscle was calculated in both groups by water displacement method and the harvested LD muscle was inset in the breast mound (Fig. 11).

- In group I: We measured the volume of the muscle flap to compare it to the volume of the excised mastectomy specimen.
- In group II: The volume measurement was done to calculate the amount of fat graft needed to inject in muscle.

Group I: De-epithelization of the skin paddle of the LD flap was done and the muscle was anchored to the pectoralis major muscle at its superior and medial borders, then it was anchored inferiorly to the infra-mammary ligament.

Group II: The flap was harvested and completely transposed in the previously formed empty breast pocket.

For the fat graft procedure, harvesting sites were accessed through incisions placed in natural body folds. An incision in the lateral hip was used to reach the lateral thigh and the flanks and another incision in the pubic region to reach the abdomen (Fig. 12).

Tumescent solution was injected into the fat donor sites. standard tumescent solution was composed of 500mg lidocaine, 1mg of epinephrine,

and 12.5mEq sodium bicarbonate added to a 1-liter solution of 0.9% normal saline [15].

Liposuction was done and the harvested fat was prepared for reinjection by using a process of eliminating fluid, blood, cell fragments, & oil [16].

The oil and aqueous layers were then discarded while the fat layer was extracted for injection.

The fat was injected in a fan like fashion in the LD muscle flap, the pectoralis major muscle and the serratus anterior muscle until the volume of the reconstructed breast was achieved (Fig. 13).

The future lower breast pole was preferentially chosen as the region to receive the greater amount of fat injection (Figs. 14,15).

Post-operative follow-up:

Immediate follow-up (first 48 hours): Patients were discharged on the second or third day once pain is tolerable and drains were looked for color and quantity every 24 hours and removed once less than 50ml.

Late follow-up:

At 1 and 3 months: Patients were examined clinically in outpatient clinic to check for seroma formation and ensure good healing of the wounds.

At 6 months: Esthetic outcome was evaluated by:

Volumetric mammography: To measure the reconstructed breast volume post operatively to notice any mammographic changes.

The modified Kyungpook National University Hospital (KNUH) Breast-Q (17): To evaluate the postoperative patient satisfaction during follow-up visits six months after surgery.

Statistical analysis:

Data entry and statistical analyses were performed using SPSS (statistical package of social sciences) version 20.0 (SPSS Inc., Chicago, IL, USA). Categorical variables were compared using the Chi-square test. Qualitative data were described using number and percent. When the quantitative data were parametric, they were shown as means, standard deviations, and ranges; when they were non-parametric, they were displayed as medians and interquartile ranges (IQR). Qualitative factors were also shown as proportions and numbers. The allowable margin of error was set at 5%, while the confidence interval was set at 95%. The *p*-value was thus deemed substantial as follows: Non-Substantial if $p > 0.05$. $p < 0.05$: Substantial. Highly substantial at $p < 0.01$.

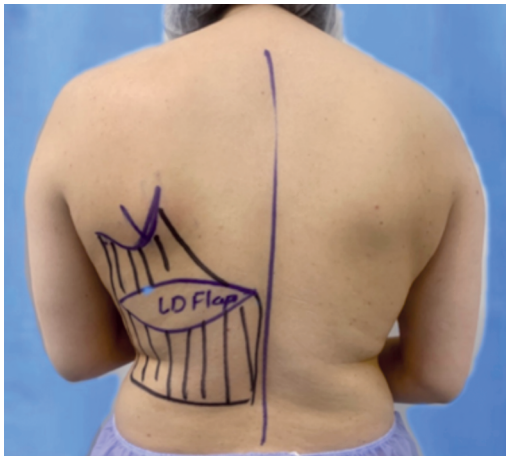


Fig. (1): Pre-operative marking of a patient in Group I, showing the design of the elliptical skin paddle of the extended LD muscle flap.

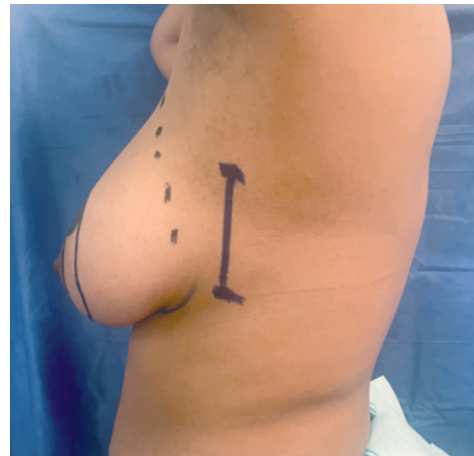

Fig. (2): A pre-operative photo, lateral view of the patient in Group II, showing the marking of the 4-6cm line in the mid axillary line.

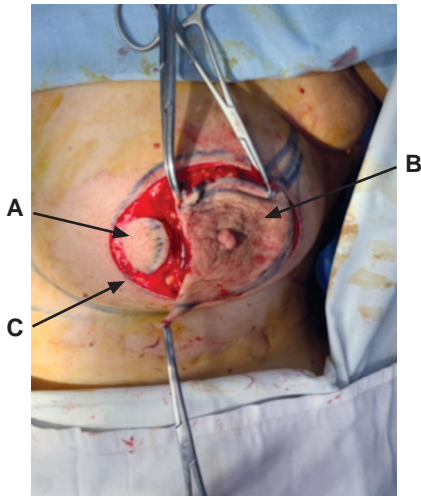


Fig. (3): Intraoperative photo of the breast after skin incisions, showing, (A): The dermal flap. (B): Excised Nipple-Areola complex. (C): Round block incision.

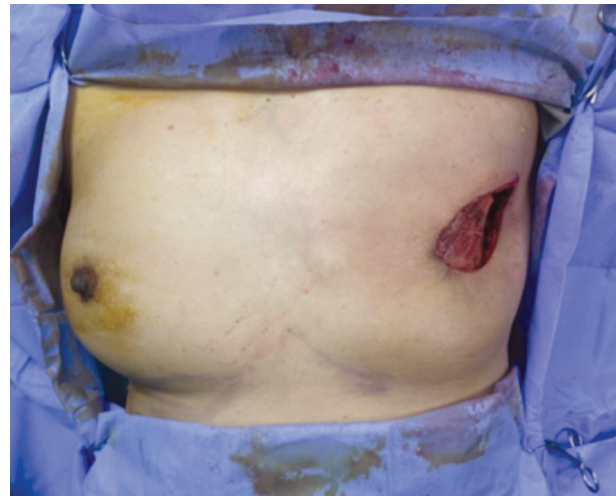


Fig. (4): Empty breast pocket after skin sparing mastectomy was done in the preparation of LD flap harvesting.

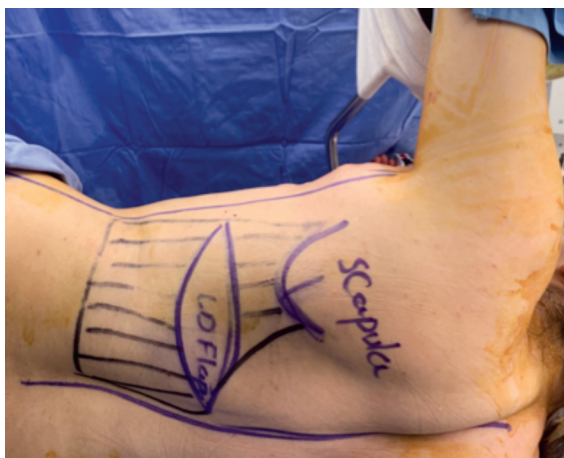


Fig. (5): Lateral posing of the patient before skin incision for flap harvest.

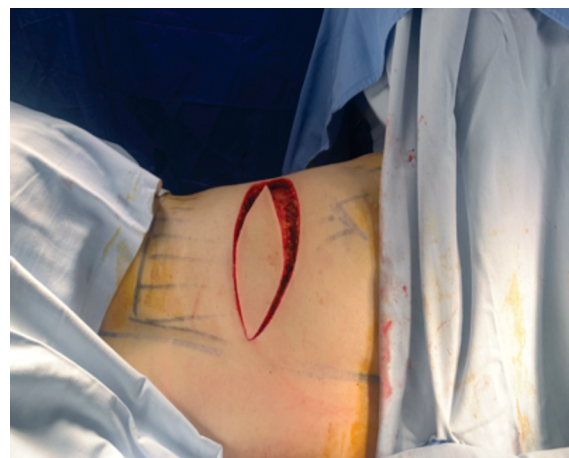


Fig. (6): Ellipse skin incision of the extended LD muscle flap.

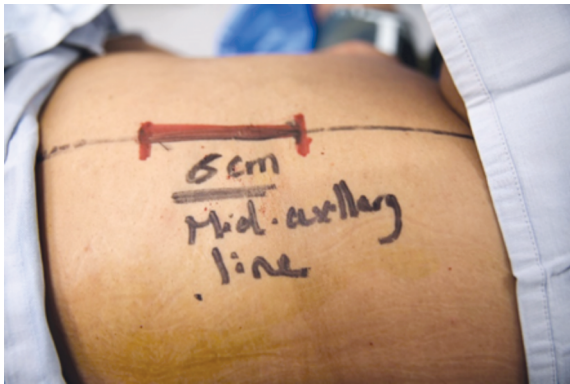

Fig. (7): Placing the patient laterally for endoscopic flap harvest through a 6cm incision in the mid-axillary line.

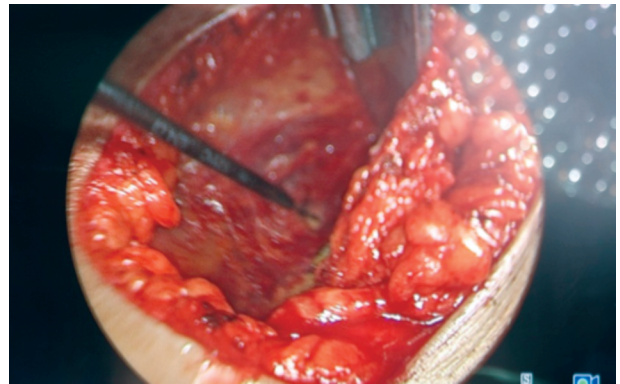


Fig. (8): Endoscopic photo of the dissection through the inferior surface of the LD muscle by a long pen diathermy.

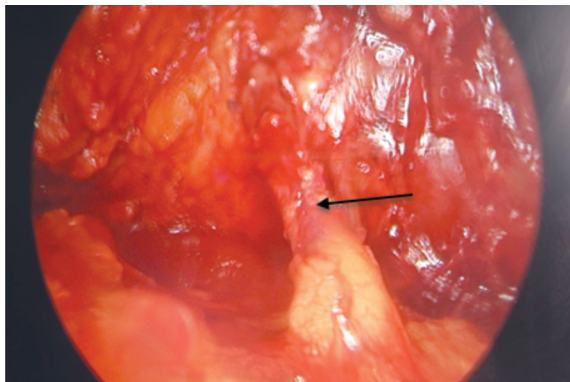


Fig. (9): Endoscopic photo showing the thoracodorsal vessels, shown by the black arrow, entering at the inferior surface of the LD muscle.

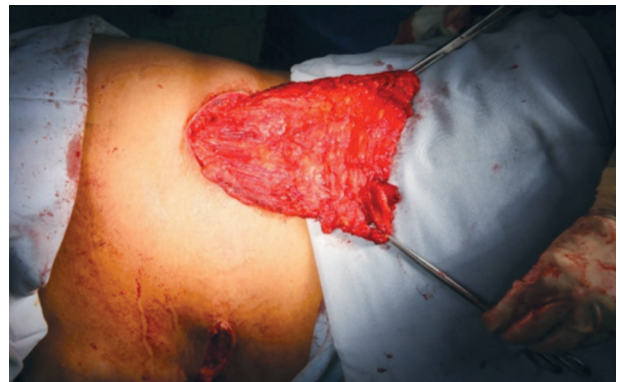

Fig. (10): Elevation of the LD muscle with the thoracodorsal bundle.



Fig. (11): Volume measurement of the LD muscle by water displacement method.

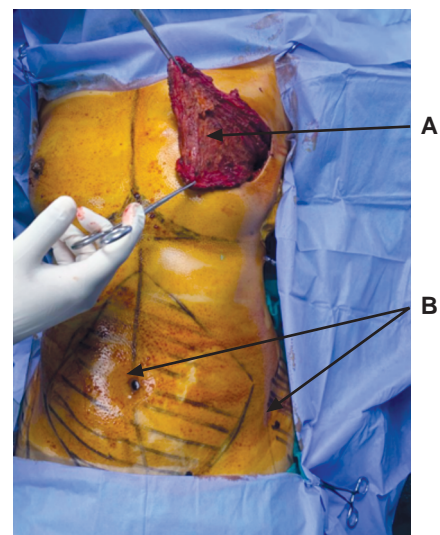


Fig. (12): (A): LD muscle flap harvesting. (B): Fat donor sites.

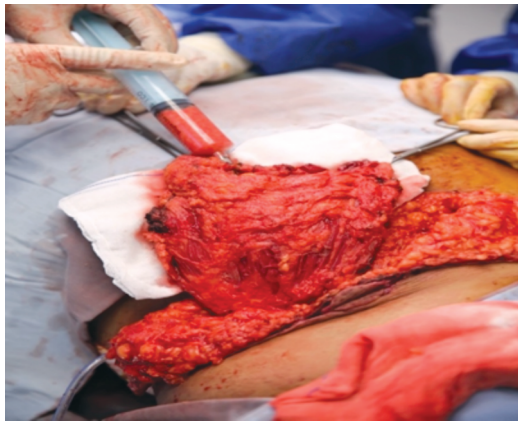


Fig. (13): Fat injection into the harvested LD muscle flap.

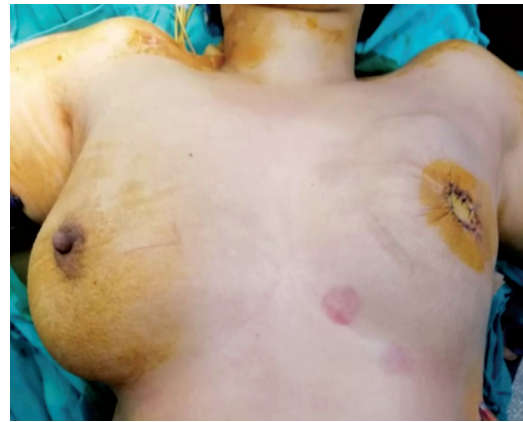

Fig. (14): Immediate post-operative photo after Skin sparing mastectomy and reconstruction with Extended LD flap and skin closure utilizing the dermal flap technique.

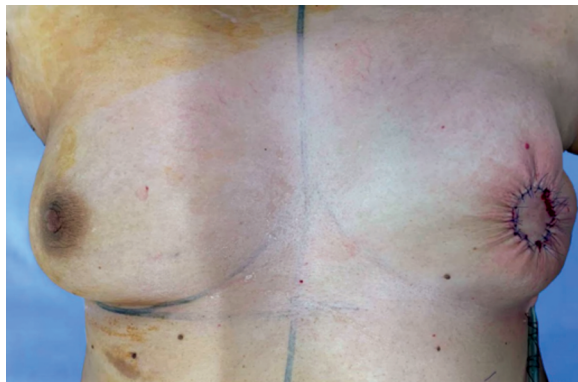

Fig. (15): Immediate post-operative photo after skin sparing mastectomy and reconstruction with Endoscopic LD flap and fat graft and skin closure using the dermal flap technique.

RESULTS

This investigation included 40 female patients who fulfilled the inclusion criteria. The study showed that there was no statistically Substantial variation between group I and group II as regard age, BMI, and menopausal status with p -value = 0.673, 0.208 and 0.343 respectively. This study showed that there was no statistical substantial variation found as regard location of breast cancer, histology, disease stage, and axillary lymph node status ($p > 0.05$).

Table (1) displays the baseline patient data and tumor features.

Table (1): Baseline characteristics of the patients and tumor features.

Variable	Group I (ExLD) N=20	Group II (EnLD) N=20	p -value
Age (years):			
Range	39-50	37-50	0.673
Mean \pm SD	42.3 \pm 12.9	43.65 \pm 3.57	
BMI:			
Range	20.0-29.2	22.1-27.9	0.208
Mean \pm SD	26.1 \pm 2.71	25.03 \pm 2.66	
Menopausal status:			
Premenopausal	No. 16, % 80	No. 17, % 85	0.343
Postmenopausal	No. 4, % 20	No. 3, % 15	
	No. 18, % 90	No. 17, % 85	
	No. 2, % 10	No. 3, % 15	
Location of breast cancer:			
Left	No. 13, % 65	No. 12, % 60	0.376
Right	No. 7, % 35	No. 8, % 40	
Bilateral	No. 0, % 0	No. 0, % 0	
Histology:			
Invasive Ductal carcinoma	No. 16, % 80	No. 15, % 75	0.390
Invasive Lobular carcinoma	No. 3, % 15	No. 4, % 20	
Other	No. 1, % 5	No. 1, % 5	
Breast cancer stage:			
I	No. 6, % 30.0	No. 7, % 35.0	0.358
IIA	No. 3, % 15.0	No. 5, % 25.0	
IIB	No. 6, % 30.0	No. 4, % 20.0	
IIIA	No. 5, % 25.0	No. 4, % 20.0	
Node positive disease:			
Yes (axillary clearance)	No. 14, % 70	No. 13, % 65	0.372
No (SNL: negative)	No. 6, % 30	No. 7, % 35	
Axillary nodal status:			
N0	No. 6, % 30.0	No. 7, % 35.0	0.500
N1	No. 11, % 55.0	No. 9, % 45.0	
N2	No. 3, % 15.0	No. 4, % 25.0	

The nipple-areola complex was removed in all patients during skin sparing mastectomy. This study declared that the mean intraoperative time was shorter in group I than in group II. The median time of the operation was 151.3±22.1 minutes in group I and 203.1±40.3 minutes in group II. There was statistically substantial variation between the two studied groups regarding volume of LD muscle flap with mean value of 472.6±50.82 and 258.4±54.63 in group I and II respectively. The median amount of fat graft in group II was 338.45±54.15ml. Table (2) displays the patients' surgical data.

Table (2): Operative data.

Variable	Group I (ExLD) N=20		Group II (EnLD) N=20		p-value
	No.	%	No.	%	
Skin-sparing mastectomy	20	100	20	100	
<i>Intraoperative time (min):</i>					
Range	120-180		180-240		0.017*
Mean ± SD	151.3±22.1		203.1±40.3		
<i>Volume of LD muscle flap:</i>					
Range	354-540		173-342		0.001*
Mean ± SD	472.6±50.82		258.4±54.63		
<i>Volume of fat graft:</i>					
Range	-		252-425		-
Mean ± SD	-		338.45±54.15		

As regarding post-operative complications (seroma and wound dehiscence at the donor site), this study declared that post-operative complications was significantly higher in group I ($p>0.05$), while there was no statistical substantial variation regarding post-operative adjuvant therapies ($p>0.05$). There were no major complications such as flap loss in both groups. Post-operative evaluation of patients is shown in Table (3).

Table (3): Follow-up up to 1-month post-operative evaluation.

Variable	Group I (ExLD) N=20		Group II (EnLD) N=20		p-value
	No.	%	No.	%	
<i>Post-operative adjuvant therapies:</i>					
Radiotherapy+chemoyherapy	8	40.0	6	30.0	0.061
Radiotherapy+Hormonal	6	30.0	8	40.0	N.S
Radiotherapy+chemotherapy +Hormonal	4	20.0	3	15.0	
Hormonal	2	10.0	3	15.0	
<i>Postoperative Complications:</i>					
Seroma	14	70	3	15	0.0001*
Wound dehiscence	3	15	0	0	0.037*
Flap loss					
Unplanned reoperation	0	0.0	0	0.0	-

This study declared that there was no substantial variation in the pre-operative volume of the breast. Although, there was a Substantial variation between both groups at the final postoperative breast volume evaluation. In group I, volume reduction ranged from 15-20% with mean value 18.1±2.81 while in group II, ranged from 30-40% with mean value 38.1±4.03, ($p=0.001$). There was statistical substantial volume reduction in group II than group I ($p<0.05$), Table (4), Fig. (16). Despite being offered an extra fat graft surgery during follow-up visits for all patients who had substantial volume decrease, none of the patients actually completed such treatments.

Table (4): Pre-operative and post-operative breast volume differences.

Volume of breast by Volumetric mammogram	Group I (ExLD) N=20	Group II (EnLD) N=20	p-value
<i>Pre-operative:</i>			
Range	381-695		0.337
Mean ± SD	546.1±115.92		532.15±90.83
<i>Post-operative:</i>			
Range	308.6-563.0		226.6-434.7
Mean ± SD	442.3±96.2		329.9±58.1
<i>Volume reduction at end of follow-up:</i>			
Range	15-20		30-40
Mean ± SD	18.1±2.81		38.1±4.03

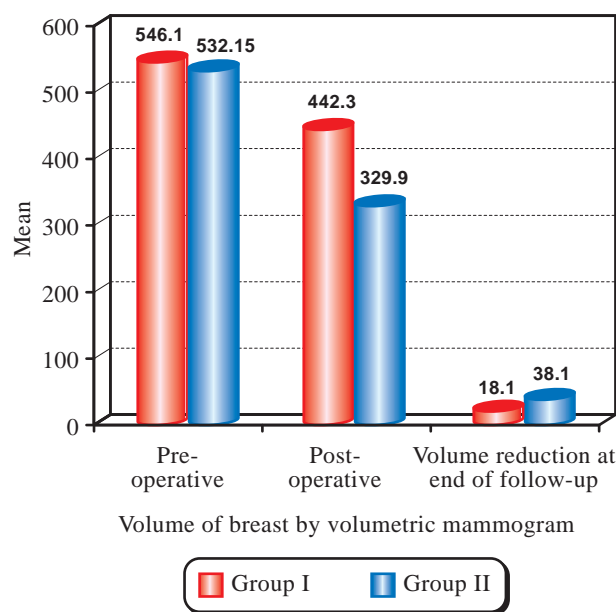


Fig. (16): Comparison of pre-operative and post-operative breast volume and the final volume reduction between the two groups.

Regarding the patient's satisfaction to the donor site scar, there was a statistical Substantial enhance in the satisfaction in the endoscopic group who had a hidden scar in the midaxillary line.

There was statistical significant decrease of the mean value regarding overall satisfaction in group (I) 3.83 ± 0.49 than the mean value in group (II) 4.26 ± 0.77 ($p < 0.05$), Table (5), Fig. (17).

Table (5): Comparison between the two studied groups reading patient satisfaction at 6 months after surgery evaluated using the modified KNUH Breast-Q.

No.	Question	Group I (n=20), Mean ± SD	Group II (n=20), Mean ± SD	p-value
1	Symmetry of my breasts	4.21±0.53	3.17±0.53	0.015*
2	My breast's size after reconstruction	4.33±0.72	3.26±0.41	0.023*
3	My breast reconstruction's shape	4.31±0.86	3.28±0.47	0.011*
4	Feel to touch my reconstructed breast	4.11±0.69	4.08±0.68	0.211 N.S.
5	My surgically repaired breast hurts	4±0.67	4.01±0.57	0.351 N.S.
6	my reconstructed breast Scar	4.23±0.53	4.17±0.83	0.277 N.S.
7	Self-confidence	3.26±0.54	4.33±0.87	0.017*
8	Donor site scar	3.4±0.49	4.3±0.54	0.0105*
9	Donor site pain	3.14±0.63	4±0.80	0.027*
10	Sexual attractiveness	3.26±0.41	4.26±0.53	0.033*
11	Overall satisfaction	3.83±0.49	4.26±0.77	0.0136*

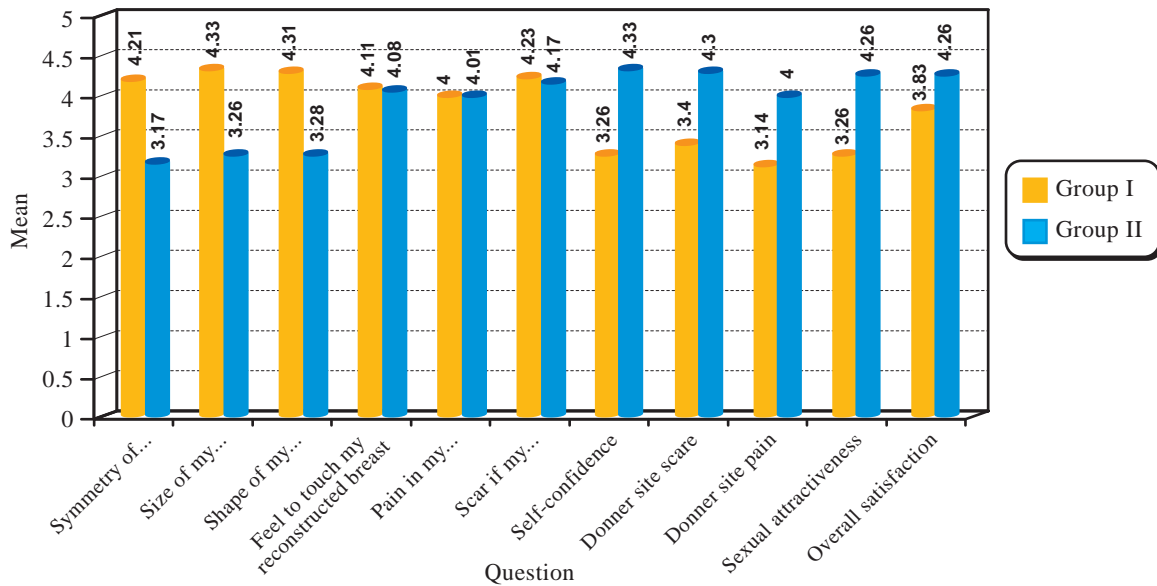


Fig. (17): Comparison between the two studied groups reading patient satisfaction at 6 months after surgery evaluated using the modified KNUH Breast-Q.

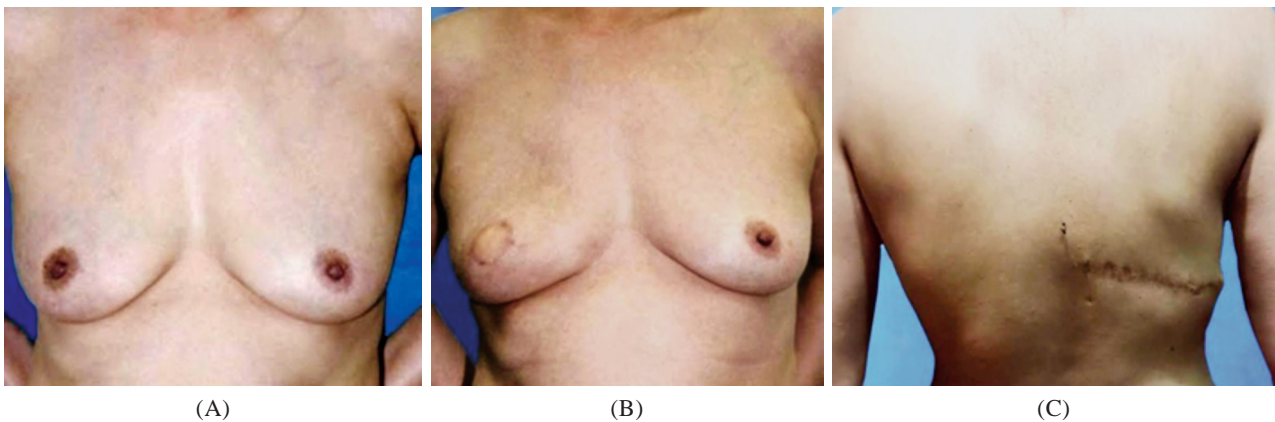


Fig. (18): (A) Pre-operative photo of a 38-year-old woman with right side cancer breast (B) Anterior view 6 months postoperative after the patient did skin sparing mastectomy and immediate reconstruction with Extended LD muscle flap, (C) Posterior view showing the donor site's scar on the back.

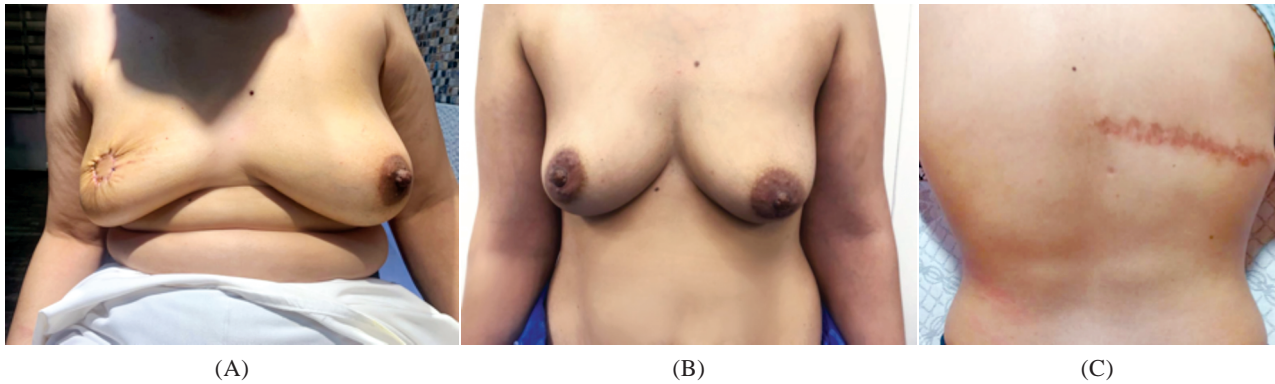


Fig. (19): 42 years old female patient with right side breast cancer, (A) Pre-operative photo, (B) Front view of the patient 6 months post-operatively after skin sparing mastectomy and immediate reconstruction with extended Latissimus dorsi muscle flap, (C) Donor site scar of the back.

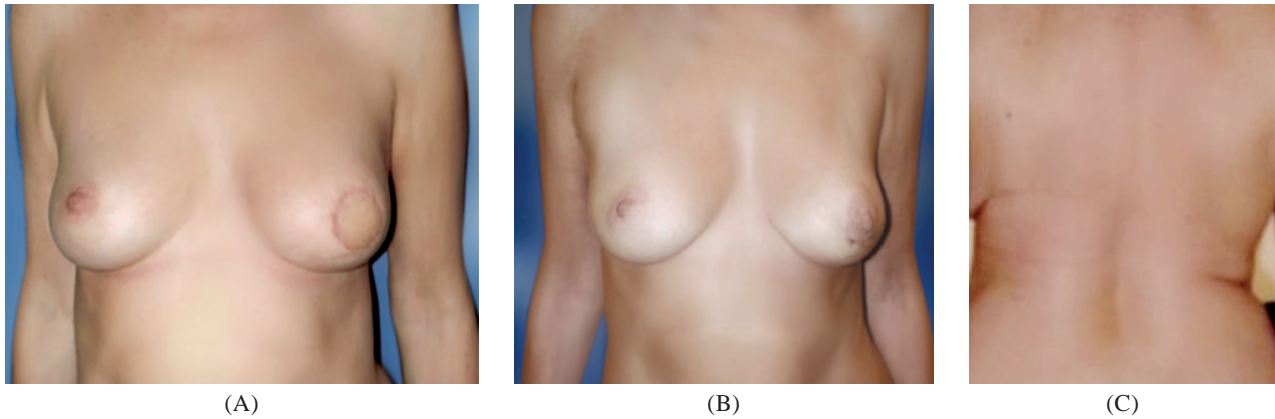


Fig. (20): 32 years old female patient with left side breast cancer, (A) Pre-operative photo, (B) Front view of the patient 6 months post-operatively after skin sparing mastectomy and immediate reconstruction with extended Latissimus dorsi muscle flap, (C) Donor site scar of the back.

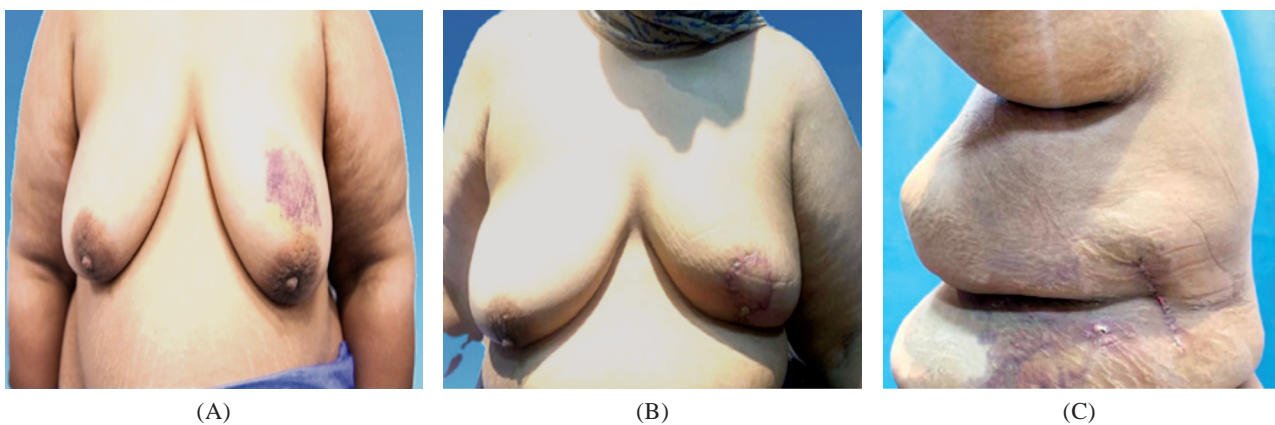


Fig. (21): (A) Pre-operative photo, anterior view, of a 45-year-old patient with left side cancer breast, (B) Anterior view, 6-months postoperative, of the patient after undergoing skin sparing mastectomy and immediate reconstruction with combined Endoscopic LD flap and fat graft, (C) Lateral view of the patient showing the scar of the donor site in the midaxillary line.

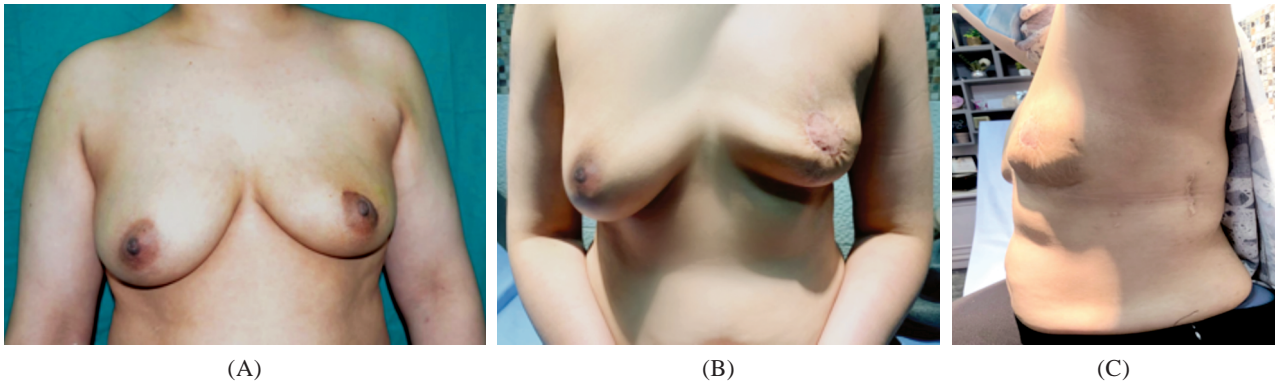


Fig. (22): (A) Pre-operative photo, anterior view, of a 41-year-old patient with left side breast cancer, (B) Anterior view, 6-months postoperative of the patient after undergoing skin sparing mastectomy and immediate reconstruction with combined Endoscopic LD flap and fat graft, (C) Lateral view of the patient showing the scar of the donor site in the midaxillary line.

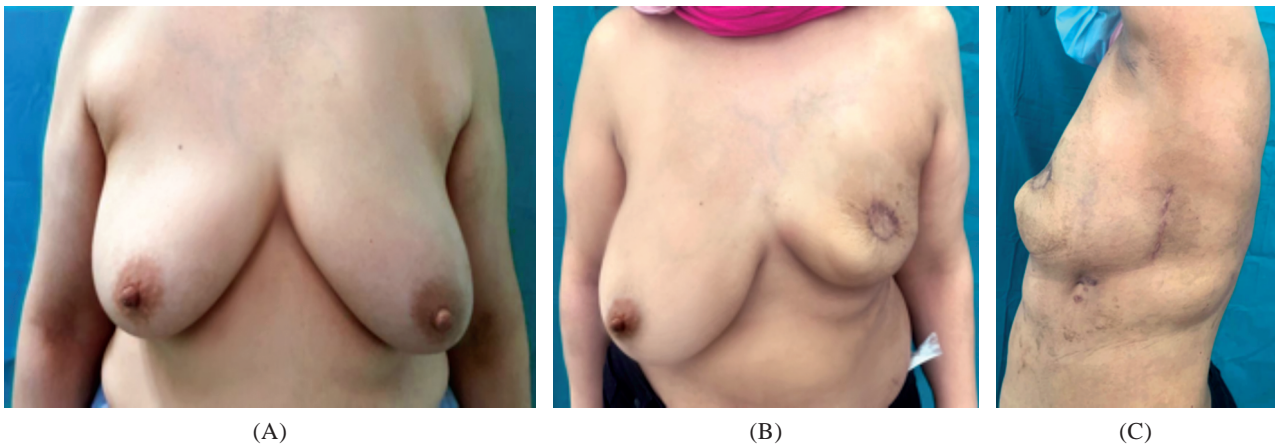


Fig. (23): (A) Pre-operative photo, anterior view, of a 39-year-old patient with left side breast cancer, (B) Anterior view, 6-months postoperative of the patient after undergoing skin sparing mastectomy and immediate reconstruction with combined Endoscopic LD flap and fat graft, (C) Lateral view of the patient showing the scar of the donor site in the midaxillary line.

DISCUSSION

The Latissimus dorsi muscle flap has been a gold standard technique in breast reconstruction to conceal the defect after skin sparing mastectomy in patients with large breast/tumor ratio [18]. The privileges of using the LD in breast reconstruction are the good blood supply, and the long pedicle of the muscle which makes the risk of flap loss almost absent. Nevertheless, traditional LD muscle harvesting leaves a long horizontal scar on the donor site and long standing postoperative donor site seroma [19].

The Endoscopic LD muscle flap with fat graft is an advanced technique for volume replacement after mastectomy that offers an easy and secure approach for autologous breast reconstruction with less donor site morbidity [12].

Regarding pre-operative data, our study reported that there was no substantial variance between the two groups as regard the mean preoperative breast volume measured by volumetric mammography, which was (514.3 ± 111.56) cc. and (531.35 ± 99.74) in Group I and II, respectively.

In this study, we clarified our endoscopic approach in the harvesting of LD muscle flap with fat graft after skin sparing mastectomy to minimize the donor site scar and improve aesthetic outcome.

Intraoperatively, better camera handling was possible because of the opening created by the midaxillary line incision. In addition, we utilized direct visualization of the initial steps, such as anterior border identification and detachment of the upper surface of the muscle, as well as endoscopic skills to use the camera in challenging

visualization areas, such as the lower surface, inferior border, and posterior border of the muscle. This technique was the same as mentioned by Ahmed and Abd El Maksoud [20].

This technique was not supported by Lee and his colleagues [21], who used instead a surgical retractor to make a space for insertion of the endoscopic camera, grasper, and energy device (Harmonic Scalpel®) to harvest the muscle.

The biggest drawback in this trial was the smaller amount of muscle compared to the conventional procedure in Group I after it had been harvested using our endoscopic approach in Group II. In our research, the mean LD muscle volume in Group I was (472.6±50.82ml). This result was more or less similar to Ahmed and his colleagues [22].

Ahmed and his colleagues [22] showed that the median volume of the traditionally harvested Extended LD flap was (446.40±70.89ml).

The median volume of the LD muscle in Group II was (258.4±54.63ml). This result of volume difference between both groups in our study was of high significant difference, *p*-value 0.001. This result came in agreement with Ahmed and Abd El Maksoud [20] whose results showed that the median volume of the endoscopically harvested LD muscle was (228.76±57.56ml).

The additional volume of the subcutaneous tissue and overlaying skin paddle seen in the conventional group may be the cause of this volume disparity.

In the current study, we make up for the lesser volume of the endoscopically harvested LD muscle by using the lipofilling procedure in the LD muscle itself and the pectoralis major muscle for volume enhancement, which would have provided us with a bigger surface area for the injection of fat. The volume of the fat graft in Group II was (338.45±54.15), to compensate for the volume difference between the two groups.

In the current study, the distinction between the two groups was evident when the operational times of the two groups were compared. In each group, the mean intraoperative duration was lower in Group I, with mean value of (151.3±22.1 minutes vs 203.1±40.3 minutes) in Group I and II respectively, with *p*-value 0.017.

Chang and his colleagues [23] showed that the median operative time of the traditional technique of extended LD flap harvest was shorter than the endoscopic technique (257.3±58.8 minutes vs 368.4±61.1 minutes) for the traditional and endoscopic groups, respectively (*p*=0.0006).

In our study, during postoperative period, consequence risk, including that of wound dehiscence and donor site seroma was assessed clinically in each group. The comparison between the two groups revealed that risk of complications was greater in traditional group than in endoscopic group.

This may be explained by the fact that when employing the extended LD flap method to support the weight of the removed breast tissue, more donor tissue is sacrificed in group I.

This result regarding the higher risk of donor site seroma and wound dehiscence in the traditional group was not supported by Yan and his colleagues [24] who reported that there was no substantial statistical variation regarding the post-operative donor site complications between the two groups.

Regarding post-operative volume reduction of the reconstructed breast in the current study, we found that, after a 6-month follow-up, the endoscopic group's breast volume decreased substantially more than that of the conventional approach, with a mean volume reduction of (18.1±2.81% vs 38.1±4.03%), *p*-value 0.001. This result came in accordance with Chang and his colleagues [23].

Chang and his colleagues [23] reported that when muscle alone was employed in the endoscopic approach, there was a roughly 15% volume loss of the original breast volume throughout the course of the long-term follow-up. This was explained by the LD muscle volume loss in the endoscopic group, in the lack of adipo-fascial tissue and as a consequence of denervation. When the observer poll asked about breast volume, shape, and symmetry, the endoscopic results were less attractive as a consequence.

Regarding the donor site scar, patients' satisfaction in the endoscopic group was substantially higher than in the conventional group, which was accounted for by the less noticeable scars on the back with the endoscopic method because the conventional method's integration of a skin flap left an unfavorable long scar in the back.

Chang and his colleagues [23] reported that, Comparative analysis of the two groups showed, very substantial rise regarding patients' satisfaction

about the donor site scar and the overall satisfaction in the endoscopic group compared to the traditional group.

Generally, in our study, regarding overall patient satisfaction, the endoscopic group outperformed the conventional group by a wide margin.

This result regarding the overall satisfaction was supported by Ahmed and Abd El Maksoud [20].

Conclusion:

Endoscopic LD muscle flap with fat graft could represent an alternative technique to Extended LD muscle flap in the setting of LD flap for immediate reconstruction in cases of early invasive breast cancer, as fat grafting is a promising solution to ameliorate the small size of the endoscopically harvested LD muscle flap. Endoscopic LD muscle flap with fat graft is better than Extended LD muscle flap in breast reconstruction regarding overall patient satisfaction and post operative donor site complications.

REFERENCES

- 1- Amin M.B., Greene F.L., Edge S.B., Compton C.C., Gershengwald J.E., Brookland R.K., et al.: The Eighth Edition AJCC Cancer Staging Manual: Continuing to build a bridge from a population-based to a more "personalized" approach to cancer staging. *CA Cancer J. Clin.*, 67 (2): 93-9, 2017.
- 2- Ferlay J., Ervik M., Lam F., Colombet M., Mery L., Piñeros M., et al.: Global Cancer Observatory: GLOBOCAN 2020 ; <https://gco.iarc.fr/today>. 2020.
- 3- Han A., Ahn S. and Min S-K.: Oncovascular surgery: Essential roles of vascular surgeons in cancer surgery. *Vascular Specialist International*, 35 (2): 60, 2019.
- 4- Weber W.P., Soysal S.D., Fulco I., Barandun M., Babst D., Kalbermatten D., et al.: Standardization of oncoplastic breast conserving surgery, [1532-2157 (Electronic)], 2017.
- 5- Rossi L., Mazzara C. and Pagani O.: Diagnosis and treatment of breast cancer in young women. *Current treatment options in oncology*, 20 (12): 1-14, 2019.
- 6- Minami C.A., Chung D.U. and Chang H.R.: Management options in triple-negative breast cancer. *Breast Cancer: Basic and Clinical Research*, 5 (1): 175-99, 2011.
- 7- Wattoo G., Nayak S., Khan S., Morgan J., Hocking H., MacInnes E., et al.: Long-term outcomes of latissimus dorsi flap breast reconstructions: A single-centre observational cohort study with up to 12 years of follow-up. *Journal of Plastic, Reconstructive & Aesthetic Surgery*, 74 (9): 2202-9, 2021.
- 8- Allen Jr. R.J. and Mehrara B.J.: Breast Reconstruction. *Plastic Surgery-Principles and Practice*: Elsevier, p. 535-64, 2022.
- 9- Ishii N., Ando J., Shimizu Y. and Kishi K.: A novel technique for large and ptotic breast reconstruction using a latissimus dorsi myocutaneous flap set at the posterior aspect, combined with a silicone implant, following tissue expander surgery, [2234-6163 (Print)], 2018.
- 10- Casella D., Nanni J., Lo Torto F., Barellini L., Redi U., Kaciulyte J., et al.: Extended Latissimus Dorsi Kite Flap (ELD-K Flap): Revisiting an Old Place for a Total Autologous Breast Reconstruction in Patients with Medium to Large Breasts. *LID - 10.1007/s00266-020-01990-x [doi]. [1432-5241 (Electronic)]*, 2020.
- 11- Clemens M.W. and Selber J.C.: Robotic Breast Reconstruction with the Latissimus Dorsi Flap. *Robotics in Plastic and Reconstructive Surgery*: Springer, p. 45-52, 2021.
- 12- Zhu L., Mohan A.T., Vijayasekaran A., Hou C., Sur Y.J., Morsy M., et al.: Maximizing the Volume of Latissimus Dorsi Flap in Autologous Breast Reconstruction with Simultaneous Multisite Fat Grafting. [1527-330X (Electronic)], 2016.
- 13- Altman D.G. and Bland J.M.: How to randomise. *BMJ.*, 319 (7211): 703-4, 1999.
- 14- Ahmed Y.S., Abd El Maksoud W.M. and Sultan M.H.: A new oncoplastic technique for removal of centrally located malignant tumors and reconstruction by a local dermoglandular flap in conservative breast surgery. *Breast Disease*, 41 (1): 175-85, 2022.
- 15- Ziabari Y.: Local Anesthetics. *Plastic Surgery-Principles and Practice*: Elsevier, p. 37-48, 2022.
- 16- Xue E.Y., Narvaez L., Chu C.K., Hanson S.E., editors.: Fat processing techniques. *Seminars in plastic surgery*, Thieme Medical Publishers, 2020.
- 17- Choi D.H., Lee J.S., Lee J.W., Lee J., Park H.Y. and Yang J.D.: A Workhorse Flap for Covering Moderate-sized Defects after Breast-conserving Surgery: Supercharged Lateral Thoracodorsal Flap. *Plastic and Reconstructive Surgery Global Open*, 9 (2), 2021.
- 18- Hamdi M. and Giunta G.: Partial Breast Reconstruction With Flaps. *Atlas of Reconstructive Breast Surgery*, 2019.
- 19- Delay E., Ganz OM. and Quoc C.H.: Autologous latissimus dorsi breast reconstruction. *Oncoplastic and Reconstructive Breast Surgery*: Springer, p. 541-51, 2019.
- 20- Ahmed Y.S. and Abd El Maksoud W.M.: Combined Endoscopy-Assisted Muscle-Sparing Latissimus Dorsi Flap Harvesting with Lipofilling Enhancement as a New Volume Replacement Technique in Breast Reconstruction. *The Breast Journal*, 2022: 7740439, 2022.
- 21- Lee J., Jung J.H., Kim W.W., Park C.S., Lee R.K. and Park H.Y.: Endoscopy-assisted muscle-sparing Latissimus Dorsi muscle flap harvesting for partial breast reconstruction. *BMC Surgery*, 20 (1): 192, 2020.
- 22- Ahmed Y.S., Abd El Maksoud W.M., Sultan M.H. and Elbakoury E.A.: Latissimus Dorsi flap enhancement by lipofilling as an immediate breast reconstruction technique for skin-preserving mastectomy. *The Breast Journal*, 27 (3): 222-30, 2021.
- 23- Chang H.P., Fan K.L., Song SY. and Lee D.W.: The traditional versus endoscopic-assisted latissimus dorsi harvest in oncoplastic surgery: A long term comparison of breast volume, aesthetics, and donor site outcomes. *Asian Journal of Surgery*, 43 (12): 1165-71, 2020.
- 24- Yan W-H., Mang J-B., Ren L-L. and Liu D-L.: Natural History of Seroma Following the Immediate Latissimus Dorsi Flap Method of Breast Reconstruction. *Chin. Med. J. (Engl.)*, 131 (14): 1674-9, 2018.