

## Case Report:

# Distraction Osteogenesis in Management of Unicoronal Synostosis: A New Idea and A Systematic Review of the Literature

TAREK M. ELBANOBY, M.D.

*The Department of Plastic and Burn Surgery, Faculty of Medicine, Al-Azhar University*

## ABSTRACT

**Background:** The objective of this article is to present a review of all reports included management of uni-coronal synostosis with distraction osteogenesis. Also, we innovated a new method in the treatment of cases of anterior Plagiocephaly in an early time using distraction osteogenesis.

**Methods:** We present a case in which the anterior plagiocephaly was treated by distraction osteogenesis of both metopic and hemicoronal in a four-month-old female patient. A comprehensive systematic review was completed using key search terms, including distraction, uni-coronal synostosis, anterior plagiocephaly, craniosynostosis. We excluded all experimental articles and picked up the clinical reports which show the usage of Distraction Osteogenesis in the management of uni-coronal synostosis. The study sample of this review consisted of 16 reports that, we analyzed them in detail.

**Results:** Over 17 years, 16 articles were published in seven journals reported the use of DO in the treatment of Unicoronal Synostosis. A total number of patients treated by DO were 120, the mean age at operations was 12 months. In the case presented, successful correction of the uni-coronal synostosis were achieved.

**Conclusion:** Distraction Osteogenesis is one of the mainstay treatments in uni-coronal synostosis. We believe that distraction of both metopic and hemicoronal in anterior plagiocephaly could improve the shape and restore the midline shift.

**Key Words:** *Osteogenesis – Unicoronal – Synostosis.*

## INTRODUCTION

Distraction Osteogenesis (DO) for patients presenting with craniosynostosis has become a mainstay treatment modality from the mid-1990s [1]. The primary goals for surgical correction are to expand the intracranial volume thereby allowing for unimpeded cerebral growth and to improve the aesthetic appearance of the child [2].

DO in synostotic plagiocephaly offers the advantages of decreased perioperative morbidity, less

soft tissue envelope restriction of expansion, and correction of cranial base angulation [3].

The objective of this article is to present a review of all reports included management of uni-coronal synostosis with DO. In addition, we innovated a new method in the treatment of cases of anterior Plagiocephaly in an early time with the distraction of the normal metopic suture in addition to the distraction of the stenosed coronal suture.

## METHODS

A review of the literature on DO of the craniofacial skeleton in cases of Unicoronal synostosis, provided by a PUBMED search (National Library of Medicine, NCBI, New Pubmed System), and a Google Scholar system, was conducted from 1998 to December 2016. Keywords applied in the search were a distraction, uni-coronal synostosis, anterior plagiocephaly, craniosynostosis. This initial search revealed more than 1180 articles. We excluded all experimental articles and picked up the clinical reports which show the usage of DO in the management of uni-coronal synostosis. The study sample of this review consisted of 16 reports that, we analyzed them in detail (Table 1). Flow sheets were made of each article with the specific parameters about DO. The author, type of distraction, indications, the number of patients, age, distraction rates and rhythms, latency and consolidation periods, the amount of lengthening, follow-up period, relapse, complications and the nature of the device were recorded for each article on the flow sheets and analyzed. Although some authors have published results of same patients in more publications, this could not be verified in detail. For analysis, the data of all different papers were used. Data were collected in (Table 2).

Table (1): Review of literature of clinical reports of DO in anterior plagiocephaly with number of cases and their mean age.

	Author/s	Year	Journal	Title	No. of cases	Age at operations (ms)
1	Kobayashi et al., [16]	1999	J Craniofac Surg	Unilateral coronal synostosis treated by internal forehead distraction.	1	
2	Imai et al. [17]	2002	J neuro surgery	Cranial remodeling to treat craniosynostosis by gradual distraction using a new device.	2	9m, 15m (m=13)
3	Satoh et al. [6]	2004	J Craniofac Surg	Hybrid of Distraction Osteogenesis Unilateral Frontal Distraction and Supraorbital Reshaping in Correction of Unilateral Coronal Synostosis	4	9m to 16m
4	Yamada et al. [18]	2005	J Craniofac Surg	Cranial Distraction for Plagiocephaly: Quantitative Morphologic Analyses of Cranium Using Three-Dimensional Computed Tomography and a Life-Size Model	4	14.5 m
5	Yong Oock et al. [19]	2008	J Craniofac Surg	Cranial Growth After Distraction Osteogenesis of the Craniosynostosis	3	
6	Choi et al. [3]	2009	J PRAS	One-piece frontoorbital advancement with distraction but without a supraorbital bar for coronal craniosynostosis	2	M=9.5 m
7	Tellado & Lema [4]	2009	J Craniofac Surg	Coronal Suturectomy Through Minimal Incisions and Distraction Osteogenesis Are Enough Without Other Craniotomies for the Treatment of Plagiocephaly Due to Coronal Synostosis	10	12-14 m
8	Park et al., [20]	2010	Pediatr Neurosurg	Rotating Distraction Osteogenesis in 23 Cases of Craniosynostosis: Comparison with the Classical	2	
9	Choi et al. [21]	2010	Prs	Method of Craniotomy and Remodeling Use of Distraction Osteogenesis to Change Endocranial Morphology in Unilateral Coronal Craniosynostosis Patients	7	14m
10	Park & Yoon [13]	2011	Pediatr Neurosurg	The Trans-Sutural Distraction Osteogenesis for 22 Cases of Craniosynostosis: A New, Easy, Safe, and Efficient Method in Craniosynostosis Surgery	8	9.1±10.2
11	Taylor et al. [22]	2014	PRS	A New Approach for the Treatment of Unilateral Coronal Synostosis Based on Distraction Osteogenesis	2	10 m
12	Osawa1 et al. [5]	2015	Child nervous system	The usage of the three-dimension distractor in the NAVID system for plagiocephaly—three case reports	2	
13	Tahiri et al. [10]	2015	J Craniofac Surg	Distraction Osteogenesis Versus Conventional Fronto-Orbital Advancement for the Treatment of Unilateral Coronal Synostosis: A Comparison of Perioperative Morbidity and Short-Term Outcomes	5	4.8±2.1
14	Shen et al. [7]	2015	PRS go	Piezosurgical Suturectomy and Sutural Distraction Osteogenesis for the Treatment of Unilateral Coronal Synostosis	1	6 m
15	Park & Yoon [8]	2016	J Neurosurg Pediatr	Transsutural distraction osteogenesis for 285 children with craniosynostosis: a single-institution experience	57	12.0±14.0
16	Jeong et al. [23]	2016	J of Cranio-Maxillofacial Surgery	Long-term follow-up of one-piece fronto-orbital advancement with distraction but without a bandeau for coronal craniosynostosis: Review of 26 consecutive cases	10	15

Table (2): Details of DO and procedures.

Author/s	type of distraction	No of distractors	Distance of distraction	Rate of distraction	Blood loss	Time of surgery (min)	Consolidation period	Latency period (d)	Activation period	Complication and specification
Kobayashi et al. [16]		1	17 mm	0.5 mm/day			2 m	5		
Imai et al. [17]		4	m=30.75		m=350ml		2-3 m	7		
Satoh et al. [6]	Unidirectional internal device	1	15mm	1mm/day	50-130 cc		20 w	3		Dural tear one case
Yamada et al. [18]		4-5		0.5-1 mm/day			4-5 m	7	3-4 w	
Yong Oock et al. [19]		2		1mm/day			8 w	4		
Choi et al. [3]		2	m=16.5mm	1mm/day		107.5	2-3m	7		
Tellado & Lema [4]	Unidirectional bone distractor system	1	35-45 mm	1mm/day	nil	90-120	3-5 w	3		Post operative Helmet
Park et al., [20]	Rotation d O	1								
Choi et al. [21]		2		1mm/day			2-3m	7		
Park & Yoon [13]	TSUDO	2.1+0.4	19.7+3.9			128.1+21.5 min	55.1+10.1	2.6+1.3		
Taylor et al. [22]		1		1mm/day	200mm		8-12 w			
OsawaI et al. [5]	NAVID system	2-3	10 mm							
Tahiri et al. [10]	Auniplanar	1	23.7	0.9 mm/d	169±72	127±15	10 w	no	26	
Shen et al. [7]		2		1.2 mm/day			2.5 m	no	15 d	The distraction-resulted skull defect was filled with Medpor
Park & Yoon [8]	TSUDO	2.7±0.6	12.8±5.6	12.8±5.6		113±33	49.1±14.2	3.0±0.5	32.9±11.4	
Jeong et al. [23]		2	28.3 mm			98 m				

## RESULTS

Over 17 years, 16 articles were published in 7 journals reported the use of DO in the treatment of unicoronal synostosis. Six reports in Journal of craniofacial surgery, two reports in each of PRS and pediatric neurosurgery, and single report in each of PRS GO, Journal of Neurosurgery, Journal of Neurosurgery: Pediatrics, Child Nervous System & JPRAS. A total number of patients treated by DO were 120, the mean age at operations was 12 months, the number of distractors used varied from one distractor in six reports, two distractors in five reports, two to three in two reports and four to five in two reports. The mean number of distractors used was 2.1/patient. The mean length of distraction was 19mm, the maximum distracted length was 45mm [4], while the minimum length was 10mm [5]. The rate of distraction was 0.5-1mm/day; average blood loss was 100cc, average operation time 117minutes, consolidation time varied between 2m to 5m, the single complication reported was a dural tear in one case [6], two reports documented special aids postoperatively helmet in 10 cases [4] and medpore in one case [7]. Types of distractor used in these studies varied from uniplanar in all cases apart from NAVID distractor in two cases and rotation distractor in 2 cases [8]. (Table 3) illustrates the data analysis.

### Case report:

A four-month-old female patient presented by right anterior plagiocephaly (Fig. 1A). She presented for the first time in March 2009. Neither of the parents had any genetic or morphologic disorders, the pregnancy was unremarkable, without maternal diabetes or infections. No other medical anomalies were identified, nor were any syndromes suspected. For specific diagnosis, the patient was admitted to

Al-Azhar University Hospital where three-dimensional computed tomography revealed a complete fusion of the right coronal suture (right Unicoronal synostosis) (Fig. 2A,B). Intraoperative measurements were done to metopic suture regarding midline shift (16mm), Rt. Frontal bone depression in the most lateral line (20mm).

The surgical plan included distraction osteogenesis without suturectomy to the patent metopic suture (Trans-Membranous Sutural Distraction Osteogenesis) and distraction osteogenesis with suturectomy (trans-sutural distraction osteogenesis TSuDo) to the stenosed Rt. Hemi coronal one (Fig. 3). The operative time was 70 minutes. Blood loss was 30ml, no need for blood or plasma transfusion.

With no latency period, the applicable distraction rate was 1/3mm/day for the metopic suture for 48 days and 2/3mm/day for the right coronal suture for 30 days. Consolidation period was three months then we remove the distractors and put plates to maintain the distraction forces.

CT two-hemisphere brain volume and both orbital index and volume were done preoperative and post activation (Fig. 2C).

Successful distraction osteogeneses for both sutures were achieved. We have seen a subjective correction of cranioorbital dysmorphology without any ocular functional problems. Intraoperative measurements were done during removal of the distractors with almost equal levels of a most lateral aspect of the forehead and midline metopic suture position. Near equal two-hemisphere brain volume after activation period and both orbital volumes equal with different orbital index preoperative and after the end of activation (Fig. 1B-F).

Table (3): Analyzed data collected, ICP; Intracranial pressure.

Total number of patients	120
Distraction length/patient (mean)	19 mm
Number of distractors used/ patient (mean)	2.1
Age of operation (mean)	12 months
Blood loss (mean)	100 cc
Time of surgery (mean)	117 minutes
rate of distraction	0.5-1mm/day
Evaluation methods	3D CT, intracranial volume, ICP

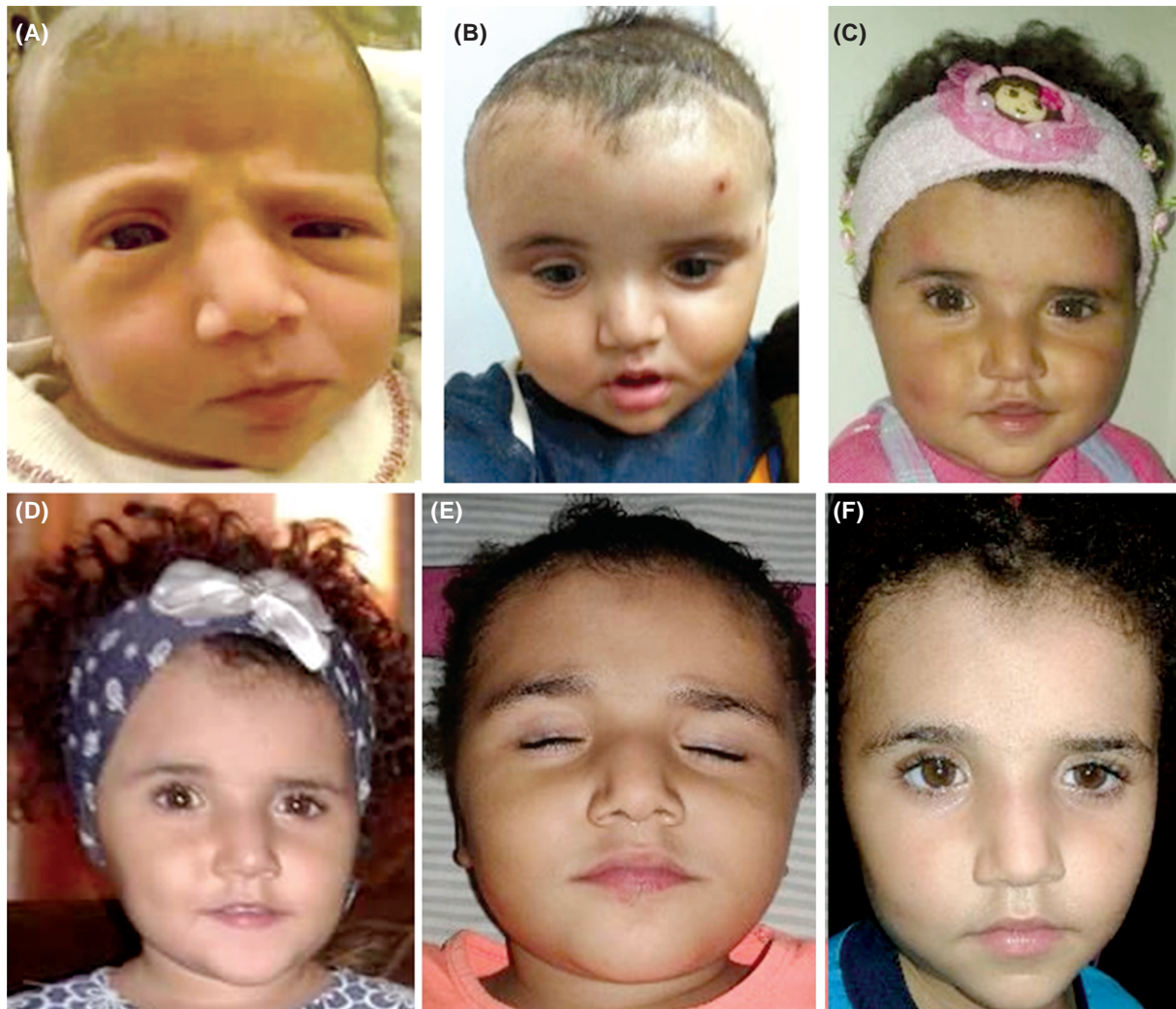

Fig. (1): A patient with uni-coronal CS before DO of both the coronal and metopic suture (A), immediately after distraction (B) six months later (C), one year later (D), two years later (E) and four years later (F).

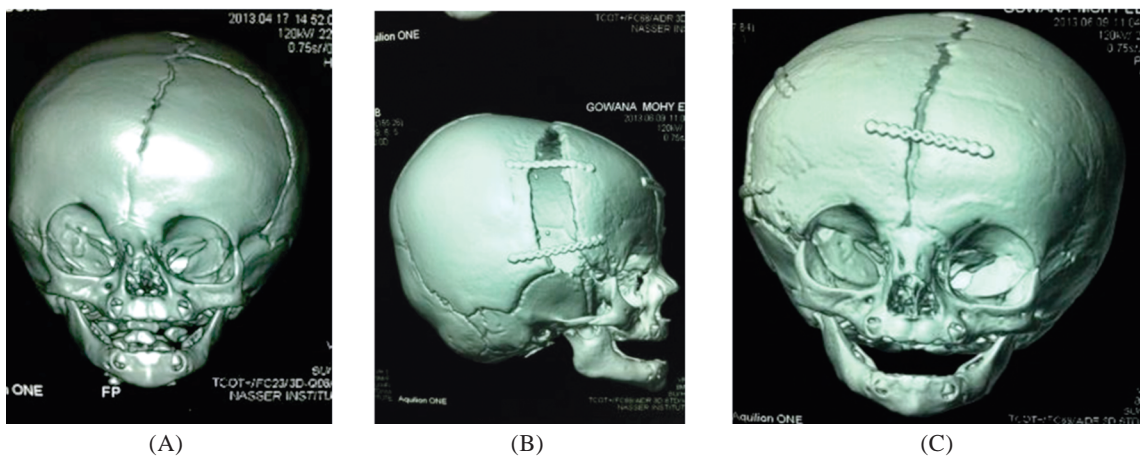


Fig. (2): 3D reconstructed CT images of the patient with uni-coronal suture craniosynostosis, preoperative (A), postoperative lateral view shows suturectomy of the fused coronal suture from the coronal suture to the junction between the coronal suture, and fronto-zygomatic suture (B), Anterior view after distraction shows the improved frontal and nasal deviation and craniofacial asymmetry (C).

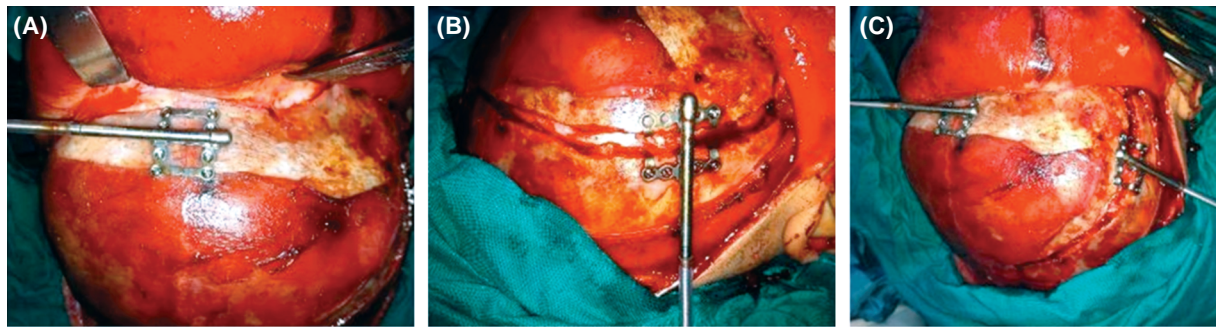


Fig. (3): Intra-operative photos; transsutural DO of the Rt unicoronal (A) and transmembranous DO of metopic suture (B), both distractors after inseting (C).

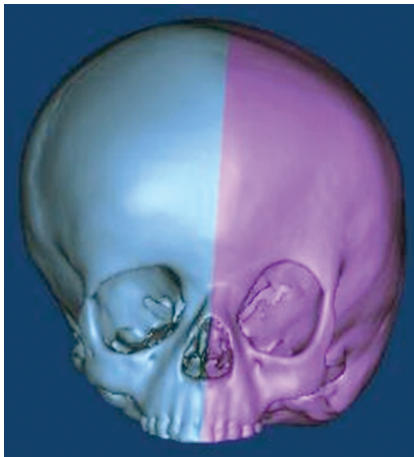


Fig. (4): 3D reconstructed CT images of the patient with unicoronal suture craniosynostosis, deviation of the nasal root and Supraorbital Rim flattening, elevation, and recession are noted.

## DISCUSSION

Premature closure of uni-coronal cranial suture induces unpleasant craniofacial deformities with less incidence of high intracranial pressure [9]. Early surgery in functional indication is mandatory however Pure aesthetic correction is difficult due to age limitations and quality of the cranial bone.

Many efforts directed to guard against the craniofacial deformities in plagiocephaly (esp. in the 1<sup>st</sup> six months of life) using DO. However, it was difficult to achieve consistent, satisfactory results and symmetric growth because of variations in growth and the degree of craniofacial deformity. As Table (1) illustrates, numerous studies since the late 1990's have published results of different techniques for surgical treatment of uni-coronal synostosis by DO. The largest series of DO in unicoronal synostosis was by park & Yoon [8]. In that study, 57 patients (mean age 13 months) had an Immediate correction of irregular head contours after distraction at a follow-up of 41.3 months. The youngest age at which operations was done reported in two studies. Tahiri et al. [10] reported

five cases with the mean age was 4.8 months while Shen et al. [7] reported a case report at the age of six months. One study reported outcomes after the minimally invasive procedure which involved many smaller incisions in achieving similar osteotomies [4]. Objective evaluation of the results was reported in 10 studies; evaluation varied from three-dimensional CT, head circumference, Scale of Intelligence.

The arrest of hemicoronal suture closure induce a shift of the metopic suture, anterior cranial base and the nasal root (Fig. 4) so, the opposite forces applied to released synostosed cranial suture not enough to restore the normal craniofacial midline. We hypothesized that coronal suture distraction alone is not sufficient to induce a direct effect on anterior cranial base, so the association of metopic suture distraction to apply direct forces to cranial base and facial component especially the nose is mandatory. On the other hand, a vital question arouses how come to distract a normal suture to induce premature sutural ossification.

Vu et al. [11] conducted a study to determine the age of closure of metopic suture, and he suggests that normal or physiologic closure of the metopic suture occurs much earlier than what has been previously described. This study establishes that metopic fusion may normally occur as early as three months of age and that complete fusion occurred by nine months of age in all patients. Bajwa et al., concluded that there is a wide variation in the normal fusion of the metopic suture. The suture may fuse between 2 and 14 months in a normal child. So the interference with the metopic suture does not induce synostosis in this age.

Many studies explain the reverse effect of Do on the frontoparietal temporal cranial suture, orbitonasal component as a facial component and the cranial base, Choi et al. [3] hypothesized that distraction of the cranium might cause stress on the skull base that could modify skull base angu-

lation deformities. Indeed, the correction of the skull base axis was maintained during the follow-up period. Although the traditional techniques were also found to correct the skull base deformities to some degree, it seems that distraction created much greater skull base axis changes.

The disadvantages of craniostyosis distraction are the need for staged operations and the discomfort associated with a long distraction period. Indeed, forehead reshaping with distraction may be somewhat limited, particularly in severe forms of synostotic plagiocephaly.

Park & Yoon [13] developed the trans-sutural distraction osteogenesis (TSuDO) operation technique of simple suturectomy and vector-controllable distraction, which can afford successful treatment for all types of craniostyosis.

In this paper, we try to perform a new method by which we can achieve both goals of treatment, relieve of increased ICP and correct the craniofacial morphological deformity by serving counteraction forces to adverse the traction forces.

In this case, we used a distractor on the patent metopic suture and placed centrally in the suture to achieve lateral and anterobasal widening and another distractor on the stenosed coronal suture after suturectomy to advance the ipsilateral frontal bone anteriorly and Correct deviation of the root of the nose.

In the cranial vault, the growth stimulus arises primarily from the expanding brain, sending signals using the dura mater [14]. As the brain expands and the cranial base synchondroses (cartilaginous bone growth plates) lengthen, the sutures respond by adding intramembranous bone at the edges of the bone fronts, such that the sutures remain approximately the same width and the cranial vault increases in size to accommodate the enlarging brain. For sutures to function as intramembranous bone growth sites, they need to remain in an unossified state, yet allow new bone to be formed at the edges of the overlapping bone fronts [15]. Based on this fact, we supposed that distracting the Membranous metopic suture is an easily and non-invasive procedure that will aid in improving the morphology of the patients and we called it Membranous Sutural Distraction Osteogenesis (MSUDO).

### Conclusion:

Distraction Osteogenesis is one of the mainstay treatments in uni-coronal synostosis. We believe that distraction of both metopic and hemicoronal in anterior plagiocephaly could improve the shape and restore the midline shift.

## REFERENCES

- 1- Barone C.M., Ferder M., Jimenez D.F., et al.: Distraction of the frontal bone outside the cranial plane: A rabbit model. *J. Craniofac. Surg.*, 4: 177-181, 1993.
- 2- Pearson G.D., Havlik R.J., Eppley B., et al.: Craniostyosis: A single institution's outcome assessment from surgical reconstruction. *J. Craniofac. Surg.*, 19: 65-71, 2008.
- 3- Choi J.W., Koh K.S., Hong J.P., et al.: One-piece fronto-orbital advancement with distraction but without a supraorbital bar for coronal craniostyosis. *J. Plast. Reconstr. Aesthet. Surg.*, 62: 1166-73, 2009.
- 4- Tellado M.G. and Lema A.: Coronal suturectomy through minimal incisions and distraction osteogenesis are enough without other craniotomies for the treatment of plagiocephaly due to coronal synostosis. *J. Craniofac. Surg.*, 20 (6): 1975-77, 2009.
- 5- Osawal H., Kato M., Nagakura M., et al.: The usage of the three-dimension distractor in the NAVID system for plagiocephaly three case reports. *Childs Nerv. Syst.*, 31: 2387-2390, 2015.
- 6- Satoh K., Mitsukawa N., Hayashi R., et al.: Hybrid of distraction osteogenesis unilateral frontal distraction and supraorbital reshaping in correction of unilateral coronal synostosis. *J. Craniofac. Surg.*, 15: 953-959, 2004.
- 7- Shen W., Cui J., Chen J., et al.: Piezosurgical Suturectomy and Sutural Distraction Osteogenesis for the Treatment of Unilateral Coronal Synostosis. *Plast. Reconstr. Surg. Glob Open*, 3.8, 2015.
- 8- Park D.H. and Yoon S.H.: Transsutural distraction osteogenesis for 285 children with craniostyosis: A single-institution experience. *J. Neurosurg. Pediatr.*, 17: 230-239, 2016.
- 9- Hompson D.N., Malcolm G.P., Jones B.M., et al.: Intracranial pressure in single-suture craniostyosis. *Pediatr. Neurosurg.*, 22 (5): 235-240, 1995.
- 10- Tahiri Y., Swanson J.W. and Taylor J.A.: Distraction Osteogenesis Versus Conventional Fronto-Orbital Advancement for the Treatment of Unilateral Coronal Synostosis: A Comparison of Perioperative Morbidity and Short-Term Outcomes. *J. Craniofac. Surg.*, 26 (6): 1904-1908, 2015.
- 11- Vu H.L., Panchal J., Parker E.E., et al.: The timing of physiologic closure of the metopic suture: A review of 159 patients using reconstructed 3D CT scans of the craniofacial region. *J. Craniofac. Surg.*, 12 (6): 527-532, 2001.
- 12- Bajwa M., Srinivasan D., Nishikawa H., et al.: Normal fusion of the metopic suture. *J. Craniofac. Surg.*, 24: 1201-1205, 2013.
- 13- Park D.H. and Yoon S.H.: The Trans-Sutural Distraction Osteogenesis for 22 Cases of Craniostyosis: A New, Easy, Safe, and Efficient Method in Craniostyosis Surgery. *Pediatr. Neurosurg.*, 47: 167-175, 2011.
- 14- Cohen M.M.: Craniostyosis: diagnosis, evaluation, and management. New York: Oxford University Press, p.454, 2000.
- 15- Opperman L.A.: Cranial sutures as intramembranous bone growth sites. *Dev. Dyn.*, 219: 472-485, 2000.

- 16- Kobayashi S., Honda T., Saitoh A., et al.: Unilateral coronal synostosis treated by internal forehead distraction. *J. Craniofac. Surg.*, 10: 467-471, 1999.
- 17- Imai K., Komune H., Toda C., et al.: Cranial remodeling to treat craniosynostosis by gradual distraction using a new device. *J. Neurosurg.*, 96: 654-659, 2002.
- 18- Yamada A., Imai K., Nomachi T., et al.: Cranial distraction for plagiocephaly: quantitative morphologic analyses of cranium using three-dimensional computed tomography and a life-size model. *J. Craniofac. Surg.*, 16: 688-93, 2005.
- 19- Kim Y.O., Choi J.W., Kim D.S., et al.: Cranial growth after distraction osteogenesis of the craniosynostosis. *J. Craniofac. Surg.*, 19: 45-55, 2008.
- 20- Park D.H., Chung J. and Yoon S.H.: Rotating distraction osteogenesis in 23 cases of craniosynostosis: Comparison with the classical method of craniotomy and remodeling. *Pediatr. Neurosurg.*, 46: 89-100, 2010.
- 21- Choi J.W., Ra Y.S., Hong S.H., et al.: Use of distraction osteogenesis to change endocranial morphology in unilateral coronal craniosynostosis patients. *Plast. Reconstr. Surg.*, 126: 995-1004, 2010.
- 22- Taylor J.A., Tahiri Y., Paliga J.T., et al.: A new approach for the treatment of unilateral coronal synostosis based on distraction osteogenesis. *Plast. Reconstr. Surg.*, 134: 176e-8e, 2014.
- 23- Jeong W.S., Choi J.W., Oh T.S., et al.: Long-term follow-up of one-piece fronto-orbital advancement with distraction but without a bandeau for coronal craniosynostosis: Review of 26 consecutive cases. *J. Craniomaxillofac. Surg.*, 44: 1252-8, 2016.