

Surgical Management of Different Grades of Gynecomastia; Retrospective Study

AMR M.E. KHATER, M.D.; TAREK ZAHRA, M.D.; MOSTAFA ABD HALIM, M.D.; OMAR OSAMA SHOUMAN, M.D. and AHMED M. ZEINA, M.D.

The Department of Plastic & Reconstructive Surgery, Faculty of Medicine, Mansoura University

ABSTRACT

Gynecomastia is the commonest clinical breast condition in males. This study had described surgical approaches done for different grades of gynecomastia. Eighty seven cases had been operated for gynecomastia were analyzed in this study from 2016 to 2019. One hundred and sixty three breasts, the clinical data regarding patients' satisfaction, breast size, breasts symmetry, shape and symmetry of the nipple areola complex and shape of their scars were evaluated. All cases were satisfied about the results of surgery; however patients with grade IV showed concerns about scars. Plastic surgeons treat many male patients that complain of breast enlargement and ask for surgical correction of their deformities. A surgical algorithm is needed for management of different grades of gynecomastia. Breast size, glandular ptosis and skin redundancy are the critical factors for the choice of the surgical technique.

Key Words: Breast – Gynecomastia – Liposuction – Nipple – Ptosis.

INTRODUCTION

Gynecomastia is a benign increase of the size of the male breast that occur secondary to proliferation of the mammary glandular component and increase of the fatty content of the male breast [1]. This condition may be secondary to hormonal imbalance between androgens and estrogens or increased estrogen receptors sensitivity. Estrogens cause increase breast vascularity, hyperplasia of the epithelial lining of the ducts, elongation and branching of the ducts and periductal fibrosis [2].

Gynecomastia starts with the florid phase where breast enlargement secondary to mammary ducts hyperplasia and increased cellularity of the surrounding stroma. After about one year, Gynecomastia passes into the fibrous phase where the stroma became more fibrous and predominates over the ductal element [3].

Gynecomastia is the commonest clinical breast condition in males that makes them ask for medical advice. It may be unilateral or bilateral. It is usually

associated with pain, anxiety, embarrassment, psychosocial discomfort and fear of malignancy [4]. However, gynecomastia is not associated with increased breast cancer risk except when it is related to Klinefelter's syndrome [5].

There are several grading systems of gynecomastia. Simon classification (Table 1) is a classification system with three grades [6]. Cordova and Moschella (Table 2) adopted another classification with four grades of severity [7].

Table (1): Cordova and Moschella's classification of different grades of gynecomastia.

Grade	Characteristics
Grade I	Increased diameter and slight protrusion limited to the areolar region
Grade II	Moderate hypertrophy of all the structural components of the breast, with the NAC above the IMF
Grade III	Major breast hypertrophy, glandular ptosis and the NAC at or 1cm below the IMF
Grade IV	Major breast hypertrophy, with skin redundancy, severe ptosis and the NAC positioned more than 1cm below the IMF

Table (2): Simon's classification of different grades of gynecomastia.

Grade	Characteristics
Grade I	Small enlargement, no redundant skin
Grade IIa	Moderate enlargement, no redundant skin
Grade IIb	Moderate enlargement with minor skin redundancy
Grade III	Gross enlargement and marked skin redundancy

The goals of surgical management of gynecomastia to restore normal shape of chest wall, removal of the inframammary crease, proper placement of nipple-areola complex (NAC), excision of skin redundancy with minimal visible scars and achievement of proper breasts symmetry. Several surgical techniques were used for treatment of various types of gynecomastia including suction assisted Liposuction, power assisted liposuction ultrasound assisted liposuction, open resection of the glandular tissues and skin reduction [8].

The aim of this study to analyze the most commonly used techniques over past three years for different grades of gynecomastia; their aesthetic outcomes and morbidities.

PATIENTS AND METHODS

A retrospective study was done from September 2016 to October 2019, 87 male cases with variable grades of gynecomastia were surgically treated by plastic surgeons. The study was approved by the Institutional Review Board (IRB) of the Mansoura Faculty of Medicine, Mansoura University; Informed consent was obtained from all patients.

One hundred and sixty male breasts with mean age from 17 to 41 years were included. Preoperative evaluation includes clinical grade of gynecomastia according to Cordova and Moschella, etiology of gynecomastia, history of previous gynecomastia surgery or bariatric surgery, ultrasound for breast tissue were included in the analysis. Patients with congenital or genetic disturbances were excluded from the study.

Postoperative analysis includes type of procedure, aesthetic outcome, complication and patient satisfaction. The results were assessed during follow up period of 6 months. All procedures were performed under general anesthesia with adjuvant local anesthesia for postoperative pain control or local anesthesia.

All patients were evaluated for clinical improvement through independent, blinded plastic surgeons and nurses, participants were asked to complete a Questionnaire of Patient Satisfaction (PSQ) to measure patient satisfaction; where: 1, not satisfied; 2, somewhat satisfied; 3, satisfied; 4, very satisfied; and 5, extremely satisfied.

After infiltration of the breast with tumescent solution (the composition of infiltration fluid was lactate ringer 1000cc + adrenaline 1mg+ lidocaine

2% on dose 25mg/kg), the following procedures were performed to our patients:

1- *Subcutaneous mastectomy*: A periareolar incision was done between 3 to 8 o'clock and subcutaneous tissue in order to expose the glandular tissue, which was completely excised apart from 10mm thickness of the gland, which was left deep to the areola to avoid the occurrence of dish deformity then hemostasis was obtained. The wound was closed in layers with no drains (Fig. 1).

2- *Suction assisted Liposuction with or without gland excision through per areolar incision*: Liposuction followed by mammary gland excision through classical periareolar incision.

3- *Ultrasound assisted Liposuction with or without gland excision through liposuction ports*: Delivery of gland was done through the same incision of liposuction in inframammary crease.

4- *Circumareolar approach (Benelli type)*: While the patient was standing upright, the midline, sternal borders, inframammary crease and areola were marked. A circle with a 25mm diameter was marked with its center was the nipple. Another circle was drawn around the previous one and the distance between the two circles was determined by skin laxity. This distance represents the shape of a doughnut and is the area of skin deepithelization and excision. Liposuction was done first followed by deepithelization of the "doughnut" shaped area (Fig. 3). Glandular excision was done and the areola was sutured to the remaining breast skin in two layers. The outer layer is a purse-string suture, which was performed to decrease the diameter of the breast skin border to match the smaller areolar diameter.

5- *Two stages breast reduction*: We performed ultrasound assisted liposuction only in the first stage and inferior pedicle breast reduction in the second stage using transverse scar breast reduction.

6- *Mastectomy through inframammary approach with free nipple grafts*: A transverse ellipse was drawn on the chest wall followed by excision of the feminine breast and the nipple areola complex was reinserted as a full thickness skin graft. Drains were inserted and wounds were closed in layers.

Postoperatively, pressure garments were applied for one month. Patients were discharged on the same day and first postoperative visit was scheduled after one week where dressing changes were done. Early complications were recorded. Patients were followed-up at the outpatient clinic every 4 weeks for a minimum of 6 months.

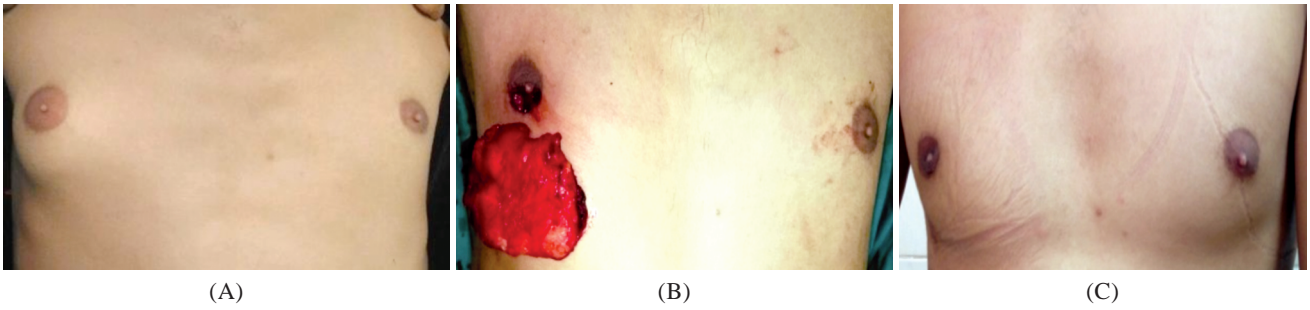
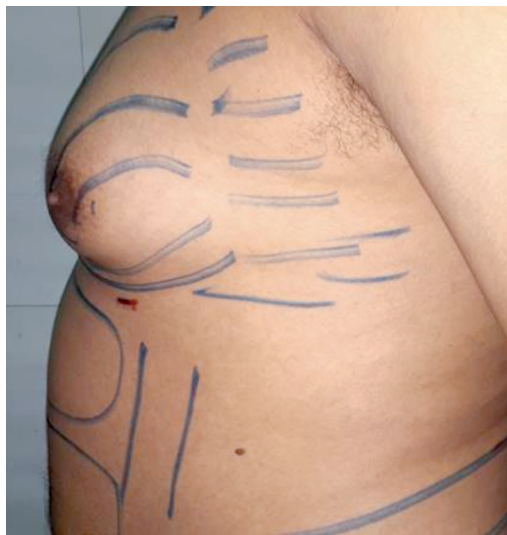
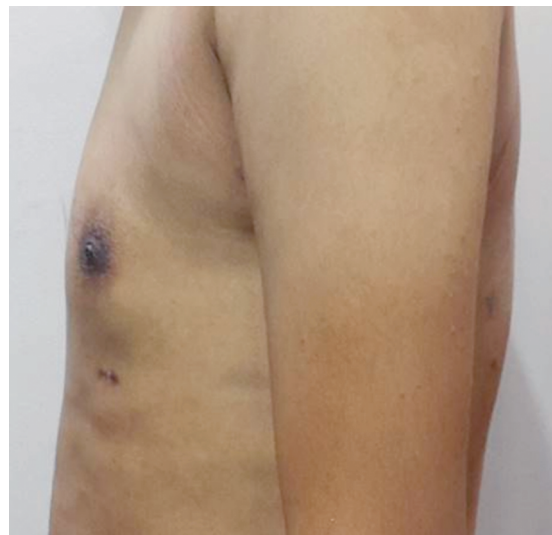


Fig. (1): A male patient was complaining of right gynecomastia grade I. (B): Intraoperative view after excision of the glandular tissues (C): 6 months Postoperative views.

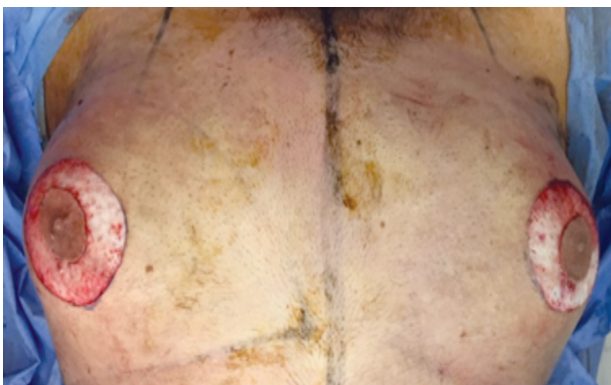


(A)

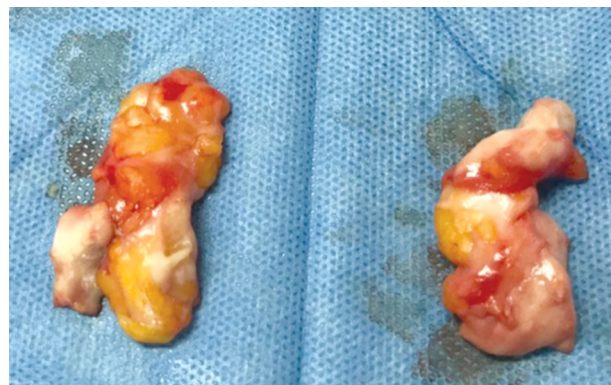


(B)

Fig. (2): (A) A male patient was complaining of bilateral gynecomastia grade II. (B) Postoperative.



(A)



(B)

Fig. (3): (A) Intraoperative excision of the circumareolar excess skin. (B) excision of the glandular tissues.

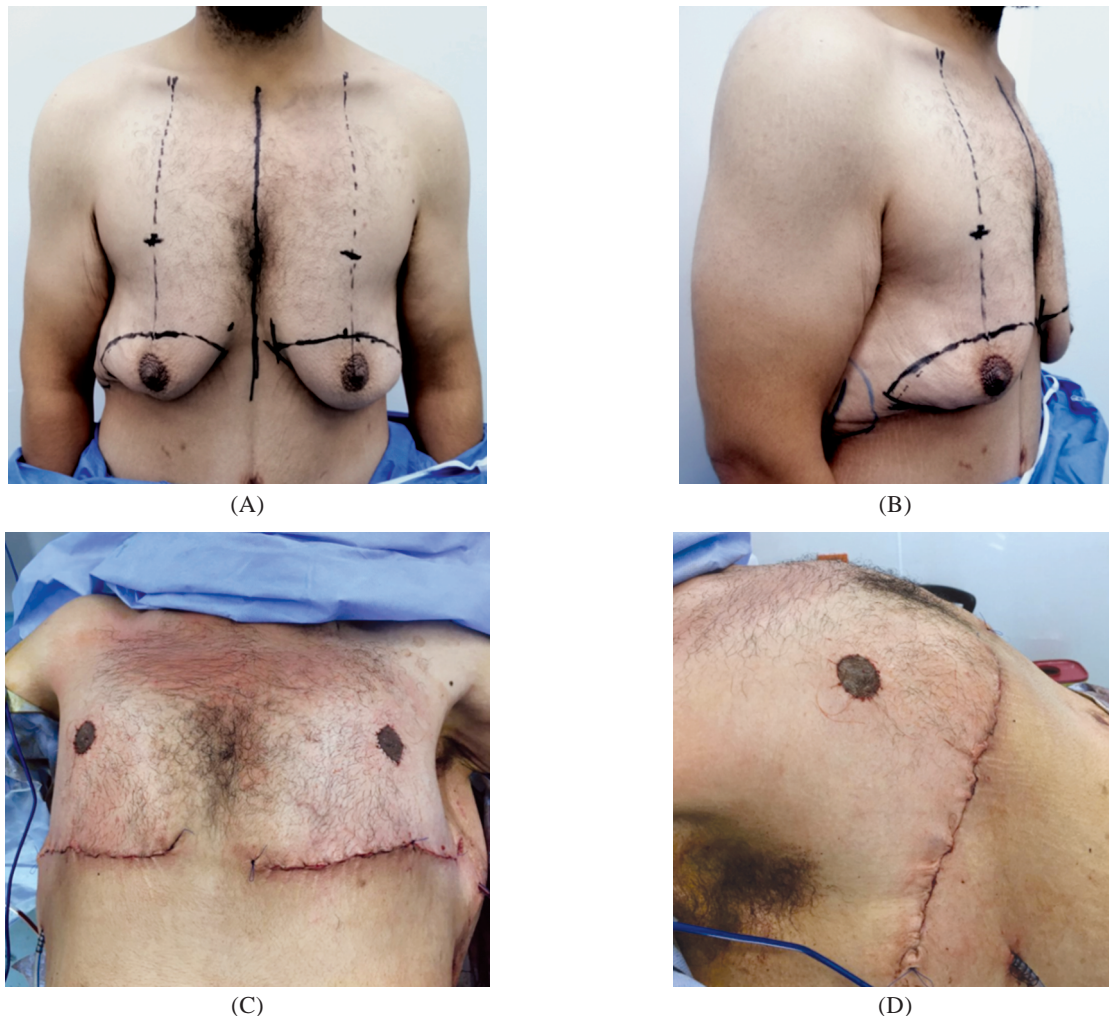


Fig. (4): (A,B) Bilateral gynecomastia grade IV. (C,D) mastectomy and free NAC graft.

RESULTS

One hundred and sixty three breasts were operated upon in 87 patients; eleven cases (13%) were unilateral (6 right, 5 left) and 76 cases (87%) were bilateral (Table 3). According to the Cordova and Moschella's classification, most of patients were presented with gynecomastia stage II (n=46, 55%) and stage I (n=17, 20%). Stage III (13%), stage IV (n=11, 13%). The causes of breast enlargement were idiopathic (n=52, 60%), obesity (n=22, 25%), hyperthyroidism (n=9, 10%), steroid therapy (n=3, 3.5%) and antipsychotic drugs (n=1, 1.2%), subcutaneous mastectomy was done in 17 cases with grade I gynecomastia, liposuction with gland excision was done in 48 cases with grade II gynecomastia, circumareolar approach (benelli type) was done in 14 cases with grade III gynecomastia, two stages breast reduction was done in 4 case with grade IV gynecomastia and mastectomy through inframammary approach with free nipple grafts was done in 4 cases with grade IV gynecomastia (Table 4), Histological examination of the removed

tissues confirmed the diagnosis of gynecomastia. Ductal hyperplasia in a background of fibrous stroma was detected. There were no metaplastic or neoplastic changes in the examined specimens.

Table (3): Patient data.

Patients data	Number of patients	%
Unilateral gynecomastia	11	12.6
Bilateral gynecomastia	76	87.35
Bariatric surgery	9	10.34
<i>Grades:</i>		
i	17	19.54
ii	46	52.87
iii	13	14.94
iv	11	12.64
<i>Etiology:</i>		
Idiopathic	52	59.77
Drug induced	4	4.59
Obesity	22	25.28
Hormonal	9	10.34
<i>Anesthesia:</i>		
Local	8	9.1
General	79	90.8

Table (4): Operative data.

Procedure	Number of patients	%	Complications	No. of patients
Subcutaneous mastectomy	17	19.54	Depressed scar	1 case
Suction assisted Liposuction (SAL)	29	33.3	asymmetry	3 cases
Ultrasound assisted (UAL)	23	26.4	Haematoma	2 cases
Circumareolar approach	14	16	Altered sensation	3 cases
Two stages breast reduction	4	4.59	Hypertrophic Scar	1 case
Mastectomy through inframammary approach with free nipple grafts	4	4.59	Altered sensation	4 cases

Postoperative complications included hematoma (2 cases) which was managed successfully by repeated aspiration and compression dressings. Prolonged hypoesthesia of the NAC was observed in 7 cases which was reversible in 6 months.

Seventy nine patients completed follow-up for six months. All patients were asked about their

satisfaction about their breast size, breasts symmetry, shape and symmetry of the nipple areola complex, shape of their scars and overall satisfaction about the surgery. All cases were satisfied about the results of surgery, however patients with grade IV gynecomastia shows concerns about the visible scars.

Table (5): Patient satisfaction.

	1 (Not satisfied)	2 (Somewhat satisfied)	3 (Satisfied)	4 (Very satisfied)	5 (Extremely satisfied)
Subcutaneous mastectomy			1	2	14
SAL				8	21
UAL			1	5	17
Circumareolar approach		1	3	10	
Two stages breast reduction				2	2
Free nipple grafts		2	2		

DISCUSSION

Plastic surgeons treat many male patients that complain of breast enlargement and ask for surgical correction of their deformities. This article had described surgical techniques for management of various grades of gynecomastia. Breast size, glandular ptosis and skin redundancy were the main factor for the choice of the surgical technique. Overall patients' satisfaction was good and complication rates were minimal.

Treatment of gynecomastia requires a multidisciplinary approach including endocrinologist, oncologist, psychologist and plastic surgeon. Despite that the gold standard treatment of gynecomastia is surgery, the selection of the proper surgical technique require thorough understanding of the various deformities exist and mastering of different surgical techniques used for surgical correction of gynecomastia including surgical excision of mammary glandular tissues, liposuction, excision of redundant skin, or any combination of the previous options [9]. The final goal is to create a male-looking chest wall with minimal scarring [10].

Specific characteristics of gynecomastia may guide surgical treatment. Several classification

systems for gynecomastia currently exist [11]. Webster classified gynecomastia according to tissue characteristics into three classes that includes class I where fibrous component predominates, class II mixed type and class III where fatty component predominates. He performed mastectomy for treatment of all classes of gynecomastia [12]. This was one of the earliest classifications of gynecomastia. Later on, Simon classified gynecomastia into three grades according to the degree of breast enlargement and skin redundancy and he performed mastectomy for treatment of all grades [6].

Since the introduction of liposuction in 1975 by Arpad and Giorgio Fischer [13] who was the first to use a hollow blunt cannula connected to a suction device to remove subcutaneous fat, liposuction was used extensively for treatment of gynecomastia [14-16]. Rohrich introduced new classification to gynecomastia where he divided his cases into four grades, he performed liposuction to treat all cases, and he used ultrasound-assisted liposuction. Staged excisions were used for treatment of cases with significant breast hypertrophy and breast ptosis [17]. However, some patients refuse multiple surgeries and ultrasound-assisted liposuction is not available in all plastic surgery

facilities. In 2017, the group in McMaster university, proposed a new classification system [18], however we found it so complicated to be applied to our cases and with no added benefits.

In reviewing the operative techniques done in this study, the Cordova classification was the most applicable classification system to this study [7]. This classification can be applied to most of patients with ease, giving different surgical option for treatment of various grades of gynecomastia, this classification addresses the specific deformities in each grade and it gives attention to the position of the nipple areola complex that is critical for the final cosmetic appearance of the operated breasts.

For treatment of cases with grade I, the periareolar incision described by Webster was used. For cases with grade II, suction assisted liposuction or ultrasound assisted liposuction was used followed by excision of the mammary gland if needed. Liposuction can remove excess fatty tissue but is not able to remove the tough glandular tissues seen in true gynecomastia. This combined technique is more reliable the technique described by Petty et al who used ultrasound-assisted liposuction and excision of the mammary gland using the arthroscopic shaver [19,20].

For treatment of cases with grade III where there is more skin laxity and breast ptosis, Circumareolar approach (Benelli type) and liposuction was used [21,22].

For treatment of cases with grade IV, liposuction was performed only in the first stage and inferior pedicle breast reduction in the second stage using transverse scar breast reduction. In case of presence of skin rolls over the lateral chest wall, breast amputation with free nipple areola graft and excision of lateral skin roll was done. In contrast to classification system by Cordova as central pedicle reduction mammoplasty technique was used for grade IV.

In this case series, complications included hematoma which occurred in 2 cases, the rate of hematoma was comparable to those found in the literature [23,24]. Seven cases developed hypoesthesia, which was reversible in 6 months. All patients were satisfied about the outcome of surgery however; the degree of satisfaction was lower in cases managed by skin excision.

Individual approach required for surgical treatment of gynecomastia depending on the grade of male breast hypertrophy and the components of breast tissue. The perfect aesthetic and surgical

outcome depend on the operative technique used. The main satisfactory item for all patients was the postoperative result of the size and breast symmetry.

Knowing the increased concern and awareness among Egyptian males about their appearance and the embarrassment having large breasts and its social impact, the strength point of this study that it is the first study to our best knowledge that discuss the satisfaction of Egyptian males suffering from gynecomastia with different surgical approaches.

The current study limitation was the small sample size and being a single center study, more centers and large sample size needed to establish a conclusion on the preference of Egyptian males suffering from gynecomastia and to conclude an algorithm that can be applied to Egyptians.

Conclusion:

Gynecomastia is a clinical term that describes a group of deformities that are confined to the enlarged male breast. A surgical algorithm is needed for management of different grades of gynecomastia. Breast size, glandular ptosis and skin redundancy are the critical factor for the choice of the surgical technique.

Acknowledgement: The authors declare that they have no conflict of interest to disclose.

Funding: None.

Conflict of interest: The authors declare no conflict of interest.

REFERENCES

- 1- Hammond D.C.: Surgical correction of gynecomastia. *Plast. Reconstr. Surg.*, 124: 61e-68e, 2009.
- 2- Ruan W., Monaco M.E. and Kleinberg D.L.: Progesterone stimulates mammary gland ductal morphogenesis by synergizing with and enhancing insulin-like growth factor-I action. *Endocrinology*, 146 (3): 1170-1178, 2005.
- 3- Bannayan G.A. and Hajdu S.I.: Gynecomastia: Clinicopathologic study of 351 cases. *Am. J. Clin. Pathol.*, 57: 431-437, 1972.
- 4- Fruhstorfer B.H. and Malata C.M.: A systematic approach to the surgical treatment of gynecomastia. *Br. J. Plast. Surg.*, 56 (3): 237-246, 2003.
- 5- Liao E.C., Kish J.B. and Hertl M.C.: Incidental discovery of bilateral breast cancer in a 24-year-old man presenting with gynecomastia. *Ann. Plast. Surg.*, 58 (6): 673-676, 2007.
- 6- Simon B.E., Hoffman S. and Kahn S.: Classification and surgical correction of gynecomastia. *Plast. Reconstr. Surg.*, 51 (1): 48-52, 1973.

- 7- Cordova A. and Moschella F.: Algorithm for clinical evaluation and surgical treatment of gynaecomastia. *J. Plast. Reconstr. Aesthet. Surg.*, 61 (1): 41-49, 2008.
- 8- Colombo-Benkmann M., Buse B., Stern J., et al.: Indications for and results of surgical therapy for male gynecomastia. *Am. J. Surg.*, 178 (1): 60e3, 1999.
- 9- Monarca C. and Rizzo M.I.: Gynecomastia: Tips and tricks. Classification and surgical approach. *Plast. Reconstr. Surg.*, 131: 863e-865e, 2013.
- 10- Lanitis S., Starren E., Read J., et al.: Surgical management of gynaecomastia: Outcomes from our experience. *Breast*, 17: 596-603, 2008.
- 11- Soliman A.T.I, De Sanctis V. and Yassin M.: Management of Adolescent Gynecomastia: An Update. *Acta. Biomed.*, 88 (2): 204-213, 2017.
- 12- Webster J.P.: Mastectomy for gynecomastia through a semicircular intra-areolar incision. *Ann. Surg.*, 124: 557-575, 1946.
- 13- Fischer A. and Fischer G.: First surgical treatment for molding body's cellulite with three 5mm incisions. *Bull. Int. Acad. Cosmet. Surg.*, 3: 35, 1976.
- 14- Abramo A.C.: Axillary approach for gynecomastia liposuction. *Aesthetic Plast. Surg.*, 18 (3): 265-8, 1994.
- 15- Hodgson E.L., Fruhstorfer B.H. and Malata C.M.: Ultrasonic liposuction in the treatment of gynecomastia. *Plast. Reconstr. Surg.*, 116: 646-653; discussion 654-655, 2005.
- 16- Lista F. and Ahmad J.: Power assisted liposuction and the pull through technique for the treatment of gynecomastia. *Plast. Reconstr. Surg.*, 121: 740-747, 2008.
- 17- Rohrich R.J., Ha R.Y., Kenkel J.M., et al.: Classification and management of gynecomastia: Defining the role of ultrasound assisted liposuction. *Plast. Reconstr. Surg.*, 111: 909-923; discussion 924-925, 2003.
- 18- Waltho D., Hatchell A. and Thoma A.: Gynecomastia Classification for Surgical Management: A Systematic Review and Novel Classification System. *Plast. Reconstr. Surg.*, 139 (3): 638e-648e, 2017.
- 19- Hammond D.C., Arnold J.F., Simon A.M. and Caparo P.A.: Combined use of ultrasonic liposuction with the pull through technique for the treatment of gynecomastia. *Plast. Reconstr. Surg.*, 112: 891-895; discussion 896-897, 2003.
- 20- Prado A.C. and Castillo P.F.: Minimal surgical access to treat gynecomastia with the use of a power-assisted arthroscopic-endoscopic cartilage shaver. *Plast. Reconstr. Surg.*, 115 (3): 939-942, 2005.
- 21- Benelli L.: A new periareolar mammoplasty: The "round block" technique. *Aesthetic Plast. Surg.*, 14 (2): 93e100, 1990.
- 22- Benelli L.C.: Periareolar Benelli mastopexy and reduction: The "Round Block". In: Spear S.L., editor. *Surgery of the breast: Principles and art.* 1st ed. Philadelphia: Lippincott-Raven, p. 685-696, 1998.
- 23- Li C.C., Fu J.P., Chang S.C., et al.: Surgical Treatment of Gynecomastia: Complications and Outcomes. *Ann. Plast. Surg.*, 69: 510-515, 2012.
- 24- Kasielska A. and Antoszewski B.: Surgical Management of Gynecomastia: An Outcome Analysis. *Ann. Plast. Surg.*, 71: 471-475, 2013.