

# The Relation between the Distance of Recto-Fascial Plication and the Intra-Abdominal Pressure Changes before and Immediately after Abdominoplasty

HELEN KAMEL MOHAMMED, M.B.B.Ch.\*\*; RIHAM LASHIN, M.D.\*;  
HISHAM MOHAMMED OMRAN, M.D.\*\* and MAHMOUD AHMED AL-SHAFAAI, M.D.\*\*

*The Departments of Plastic Surgery\* and General Surgery\*\*, Faculty of Medicine, Ain Shams University*

## ABSTRACT

**Background:** Abdominoplasty surgery involves excision of redundant abdominal skin flap and, in most cases, involves restoring weakened anterior abdominal wall muscles creating an abdominal profile that is smoother and firmer. Diastasis recti caused by anterior abdominal wall weakness. It happens because the space between left and right recti muscles has been widened. Surgical correction for diastasis during the abdominoplasty can be considered as a definitive way for correction of diastasis by performing a plication or folding of the linea alba, this results in a tighter abdominal wall.

**Aim of Work:** Is to evaluate the relationship between the distance of recto-fascial plication and intra-abdominal pressure (IAP) changes before and immediately after abdominoplasty.

**Patient and Methods:** This study included 75 female patients, ageing between 24-57 years old, with mean age of 43.3 years. Patients complained of abdominal redundancy after childbirth, or post massive weight loss, with weak anterior abdominal wall muscles. The diastasis width was measured intraoperatively at three levels (3cm above the umbilicus, at the umbilicus, and 3cm below the umbilicus) before performing recto-fascia plication. Recto-fascial plication have been performed for all patients during their abdominoplasty procedure in two layers. Intra-abdominal pressure (IAP) variation, before and immediately after rectus sheath plication were measured using U-tube technique. Statistical analysis of all measurements were done.

**Results:** Statistical analysis showed that the mean value of diastasis above and at the umbilicus didn't differ significantly, however it was significantly lower below the umbilicus compared with the other two levels. Comparing the pre and postoperative IAP showed non-statistically significant increase of IAP postoperative. Most importantly, statistics showed that there is a statistically significant positive correlation between the IAP immediately after surgery and the distance of recto-fascial plication especially above the umbilicus. Complication rate in the current study was 2.6%.

**Conclusion:** As a result of our current study, rectus diastasis width is significantly correlated with the IAP immediately after abdominoplasty, therefore the larger the width of the rectus diastasis, the more increase of IAP that would happen immediately after abdominoplasty.

**Key Words:** Abdominoplasty – Recto-fascial plication – Intra-abdominal pressure changes – U-tube test.

## INTRODUCTION

Abdominoplasty or "tummy tuck" is a common cosmetic surgery procedure with a percentage of 65% of patients worldwide. It is used to make the abdomen flatter and more firm. The surgery involves the removal of excess skin and fat from the middle and lower abdomen and tightens the muscle and fascia of the anterior abdominal wall. The restoration of the integrity of the abdominal wall by abdominoplasty and muscle plication provide dynamic support and protect the abdominal contents [1].

This type of surgery is usually sought by patients with apron abdomen or sagging skin after multiple pregnancies, normal aging process, and frequent or rapid changes in massive weight loss patients. The condition can also occur in obese men or in women who have never been pregnant as obesity can cause diastasis recti because the excess fat deposits put additional pressure on the abdominal wall muscles, long- or short-term swelling of the abdomen related to fluid inside of the abdominal cavity from conditions such as cirrhosis of the liver or cancer within the abdomen, and advanced ages. Whatever the reasons are, abdominoplasty is an effective procedure for improving the appearance of the abdomen and defining the waistline [2].

Diastasis of recti is commonly defined as a gap of roughly 2.7cm or greater between the medial edges of rectus abdominus muscles. This condition has no associated morbidity or mortality [3].

The distance between the right and left rectus abdominus muscles is created by the stretching of the linea alba, and consists of a connective collagen sheath created by the aponeurosis insertions of the transversus abdominus, internal oblique, and external oblique muscles. Diastasis of rectus abdominus muscle occurs mainly in pregnant or postpartum women, the condition is caused by the stretching of the rectus abdominis by the growing uterus. It is more common in multiparous women due to repeated episodes of stretching. When the defect occurs during pregnancy, the uterus can sometimes be seen bulging through the abdominal wall beneath the skin. It was reported that women older than 30 years are more susceptible to develop diastasis recti [4].

However, conservative treatment to diastasis of recti in the form of muscular exercises and physiotherapy can somehow help to reduce the distance of diastasis recti, but its benefit as curative treatment for diastasis still doubtful [5]. While surgical correction for diastasis during abdominoplasty can be considered as a definitive way for correction of diastasis by performing a plication or folding of the linea alba and suturing them together, this results in a tighter abdominal wall. The patient will notice improvement immediately after surgery, but final results may take several months to become apparent. The outcomes of abdominoplasty surgery will be permanent but the patient will be required to follow proper diet and exercise regimen to maintain the results [6].

Several previous studies investigated the changes that occur with intra-abdominal pressure following abdominoplasty [7-12], but none of them studied the relationship between the distance of recti diastasis and intra-abdominal pressure (IAP) changes.

The current study will validate these previous studies by demonstrating the changes in intra-abdominal pressure (IAP) following plication of recti in abdominoplasty, and relating these changes of intra-abdominal pressure (IAP) to the distance of plication between the medial borders of both recti.

#### *Aim of work:*

Aim of this study is to evaluate the relationship between the distance of recto-fascial plication and intra-abdominal pressure changes during and immediately after abdominoplasty.

### **PATIENTS AND METHODS**

The current study is a cross sectional study. It included 75 female patients, who meet the inclusion

criteria which involve: Healthy women over 24 years, and less than 60 years, with abdominal tissue excess after childbirth, or post massive weight loss patients, with weak anterior abdominal wall and diverticulation of recti upon clinical examination. Exclusion criteria for this study include: Smoker, diabetic, hypertensive, cardiac patients, patients younger than 24 years, and patients older than 60 years old, patients with evidence of umbilical hernia or previous mesh use in the abdomen, and patients with previous abdominal surgery.

Patients have been recruited from El-Demerdash educational Hospital (Plastic Surgery Department, Faculty of Medicine, Ain Shams University), and Al-Jamila private Hospital at Al-Mokattam city. The study performed in a period from March 2017 to September 2018.

Informed consent was taken from patients undergoing the abdominoplasty surgery, patients was informed about objectives of the research and are entitled to choose whether or not to take part. Their decision was voluntarily and they were competent to understand what is involved. Consent forms was designed to assure the protection of their rights.

In this study we investigated if there is a relationship between rectus diastasis width and the increase of intra-abdominal pressure, to evaluate this correlation before and immediately after plication of anterior rectus sheath during abdominoplasty procedure. The diastasis width will be measured at three levels (3cm above the umbilicus, at the umbilicus, and 3cm below the umbilicus). Rectus plication have been performed for all patients during their abdominoplasty procedure in two layers (the first layer with interrupting stitches using PDS 1, and the second layer on top of it with continuous suture using PDS 1 also) [8]. Cross-sectional study will be applied to the sample, intra-abdominal pressure (IAP) variation, before and immediately after rectus sheath plication were measured using U-tube technique (Fig. 1), [13,14].

#### *Operative technique:*

##### *Preoperative markings and photography:*

Marking for the surgery will be done while the patient is standing (wearing her usual style of underpants of her choice), determining the area of liposuction which include the central supra-umbilical area and flanks, photography is achieved with precise consistency of positioning, lightening and background.

Determination of redundant abdominal skin by pinch test was done, marking the incision that will

be done 7-9cm from the labial cleft, the excess skin and fat to be excised are usually from the umbilicus to the pubis vertically, and from one anterior superior iliac spine (ASIS) of one side to the other side horizontally.

#### *Anesthesia:*

The choices of anesthesia include intravenous sedation and general anesthesia, urinary catheter will be applied to all patients.

#### *Surgical steps:*

Infill of tumescent (1/500.000) adrenaline 1mg to saline solution, and wait for 15-20 minutes until adrenaline is effective. Traditional liposuction of the pre-marked area on the flanks, supra-umbilical area was done with liposuction cannula (size 4) attached to a suction machine [15].

Lower transverse abdominal incision was done which include skin, supra-scarpal fat, scarpas fascia, sub-scarpal fat, reaching down to the level of anterior rectus sheath.

Dissection of the upper abdominal flap upward up to the level of umbilicus with thermal cautery, then circumferential incision was made around the umbilicus skin, which is now detached from the dissected abdominal flap and keeping it attached to the anterior rectus sheath and was marked at 12 o'clock position and 6 o'clock position to prevent accidental rotation of the umbilicus at time of repair. The skin and abdominal flap are dissected centrally above the umbilicus cephalad in a tunnel up to the xiphisternum centrally, the dissection was limited laterally in the supra-umbilical area (Fig. 2).

Measuring of diastasis recti in centimeters was done before performing the recto-fascia plication, it was measured directly by sterile ruler at three levels in relation to umbilicus, 3cm above the umbilicus (Fig. 3), at the level of umbilicus (Fig. 4), and 3cm below the umbilicus (Fig. 5).

Plication of anterior rectus sheath was done in two layers by interrupted sutures followed by continuous suture using PDS 1 (Fig. 6), [8].

After the abdominal flap is dissected all the way up to the rib cage, and the muscle is tightened, the operating table is partially flexed, bringing the patients back up and flexing the hips. The excess skin is pulled downward past the incision, and the excess skin is marked with a surgical marker. The excess skin is then excised [15].

The incision is temporarily closed with clamps so that the contours can be assessed. The umbilicus is still attached by itself to the abdominal wall, underneath the abdominal skin flap transposition of the umbilicus was done. A new site on the abdominal skin flap was marked just above the underlying umbilicus and a new transverse hole was made in the skin. It is through this hole that the umbilicus is now pulled through and sutured to create a new umbilicus. The umbilicus will now have a scar around it in its border, but this is usually not well seen [15].

Actually, the abdominal skin is now tight and this supports the umbilicus upwards, the umbilicus now has a vertically oriented elliptical appearance which is very youthful in appearance, after the umbilicus is relocated to its new home, the abdomen is now prepared for closure [15].

Closure of skin in layers was done (scarpas fascia with PDS zero, subcutaneous layer and skin with monocryle 2/0). Insertion of a drain was done for all patients before final closure as seen in Fig. (7).

Measuring the intra-abdominal pressure (IAP) was done using the U-tube technique with a urinary catheter applied to the patient, a ruler with centimetres is placed vertically at zero point which placed at the pubic symphysis as shown in Fig. (1), the urinary catheter is then raised and the proximal aspect of the urinary drainage bag will be levelled with the starting point of the ruler, finally measurements is taken using the fluid column that is formed (Figs. 1,13,14). The intra-abdominal pressure (IAP) in the current study was measured twice, it was measured before recto-fascia plication and again measured immediately after recto-fascia plication by U-tube technique (Fig. 8).

Dressing the wound with sterile dressings was done, and application of a proper compression garment to the abdomen was also done to limit formation of seroma, hematoma, and edema.

#### *Sample size calculations and statistical analysis:*

Sample size is calculated according to the following equation [16]:

$$(Z_{\alpha/2})^2 \times P(1-P)/d^2$$

- $Z_{\alpha/2}$  = 1.96 (The critical value that divides the central 95% of the Z distribution from the 5% in the tail).
- P=Percentage of cases who required re-suturing of wound of abdominoplasty=5% [9].

- D=Absolute error of precision=5%.
- According to above equation the sample size will be 75 cases after adding 10% dropout.

**RESULTS**

The study enrolled 75 healthy female patients, with age ranging from 24-57 years old, with mean age of 43.3 years old as shown in Table (1), with no history of previous surgery or mesh application to the abdominal wall. Patients complained of apron abdomen with anterior abdominal wall bulge due to weak anterior abdominal wall muscles.

Recti diastasis had been measured during abdominoplasty procedure after dissection and undermining the upper abdominal flap and before performing the recto-fascial plication. It was measured at three different levels (3cm above the umbilicus, at the umbilicus, and 3cm below the umbilicus). Statistical analysis for these measurements was done, showing that the diastasis distance above the umbilicus was ranging from 6-16, with mean value of 9.84, the diastasis distance at umbilicus was ranging from 6-13, with mean value of 9.64, and the diastasis distance below the umbilicus was ranging from 5-12, with mean value of 8.72. Concluding that the mean value of diastasis above and at the umbilicus didn't differ significantly, however it was significantly lower below the umbilicus compared with the other two levels as shown in Table (2).

Before surgical procedure, we measured the IAP for each of the 75 patients included in the study, and statistically analyzed showing that the preoperative IAP was ranging from 4-44, with mean value of 11.04. Immediately after recto-fascia plication, the IAP was measured again and showed that the postoperative IAP was ranging from 6-17, with mean value of 11.40 ( $p=0.699$ ), as shown in Table (3). Comparing both values statistically showed non-statistically significant increase of IAP postoperative as shown in Table (4), using paired *t*-test (Fig. 9).

When analyzing the correlation between post-operative IAP and recti diastasis at the 3 different levels among studied patients statistically, results showed that positive significant correlations were present between postoperative IAP and recti diastasis at the 3 different levels, being highly significant above the umbilicus, as shown in Table (5), (Figs. 10-12).

Complication rate in the current study was 2.6% (2 out of 75 patients), both of them complicated with small area of central necrosis to the abdominal

wall flap, around 5-12 days post-operatively. Excision and debridement for an area at the centre of the repair (maximum tension point) was required. The patient had a frequent dressing till healing was achieved in the complicated area. And non of them needs any further surgical intervention. Otherwise, in our patients group, all participants had been satisfied with the aesthetic results achieved from surgery.

Table (1): Show the age of patients in the study group.

		Patients N=75
Age (years)	Mean±SD	43.32±8.60
	Range	24-57
	Median	43
	IQ range	11

Table (2): Show recti diastasis distance measurement at 3 different levels (3cm above umbilicus, at the umbilicus, and 3cm below the umbilicus) among the studied patients.

		Studied patients N=75
Recti Diastasis Above Umbilicus	Mean ± SD	9.84±2.62
	Range	6-16
	Median	9
	IQ Range	3
Recti Diastasis At Umbilicus	Mean ± SD	9.64±2.07
	Range	6-13
	Median	10
	IQ Range	3
Recti Diastasis Below Umbilicus	Mean ± SD	8.72±1.92
	Range	5-12
	Median	9
	IQ range	2

Table (3): Show Measurements of IAP before and immediately after recto-fascial plication among studied patients.

		Studied patients N=75
IAP pre-operative	Mean ± SD	11.04±9.35
	Range	4-44
	Median	9
	IQ range	6
IAP post-operative	Mean ± SD	11.40±3.19
	Range	6-17
	Median	11
	IQ range	5

Table (4): Show comparison between IAP before and immediately after plication among studied patients.

	Pre-operative	Post-operative	<i>t</i>	<i>p</i> -value
IAP Mean ± SD	11.04±9.35	11.40±3.19	-0.388	0.699 NS*

\*NS: Non-statistically significant difference.

Table (5): Show correlation between IAP postoperative and recti diastasis at three different levels among studied patients.

	IAP Postoperative	
	<i>r</i>	<i>p</i> -value
Recti Diastasis Above Umbilicus	0.506	0.000*
Recti Diastasis at Umbilicus	0.494	0.000*
Recti Diastasis Below Umbilicus	0.342	0.003*

Pearson correlation.

\*Statistically significant difference.

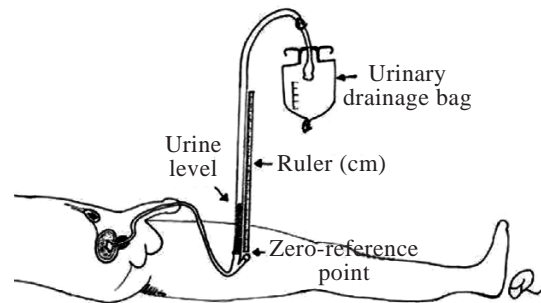


Fig. (1): U-Tube technique. (Lee, 2012).

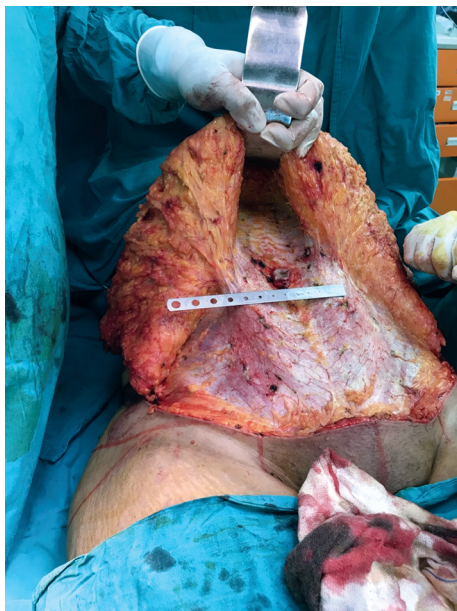

Fig. (2): A Photo show dissection of the upper abdominal flap upward to the level of umbilicus followed by dissection of a tunnel at the supra-umbilical area.

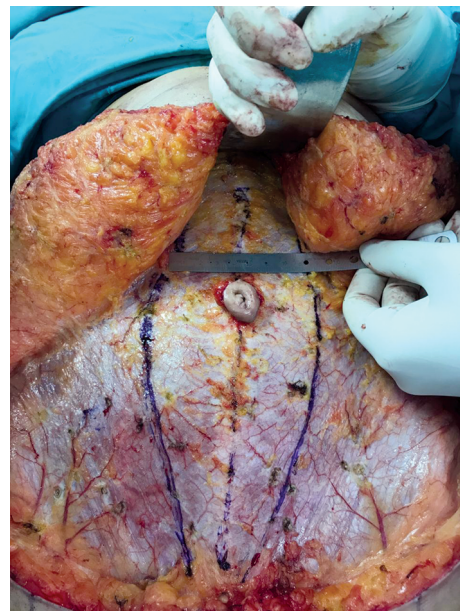

Fig. (3): A Photo show measuring the recti diastasis distance 3cm above the level of the umbilicus before performing recto-fascial Plication.

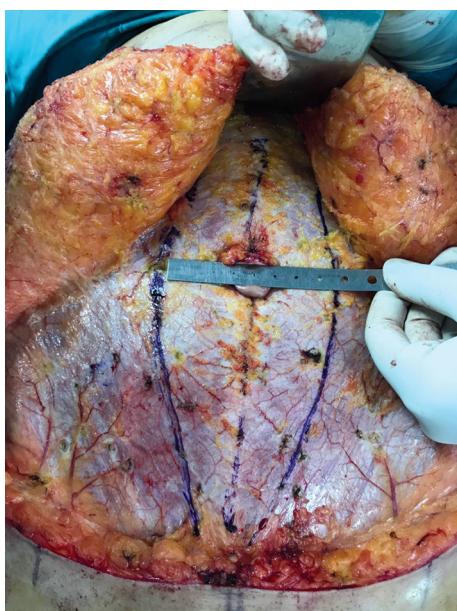

Fig. (4): A Photo show measuring the recti diastasis distance at the level of the umbilicus before performing recto-fascial plication.

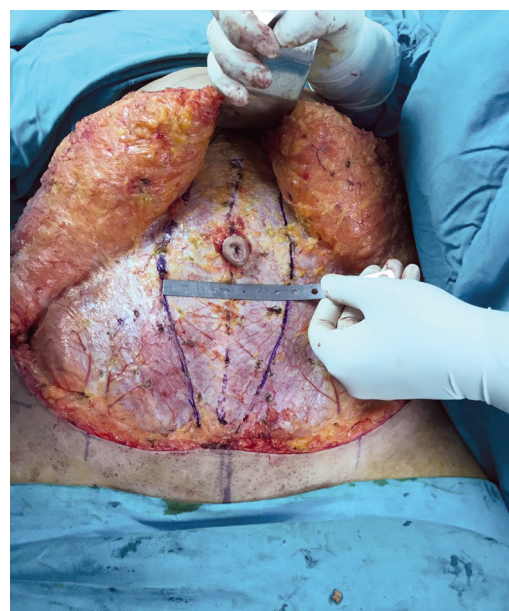


Fig. (5): A Photo show measuring the recti diastasis distance 3cm below the level of the umbilicus before performing recto-fascial plication.

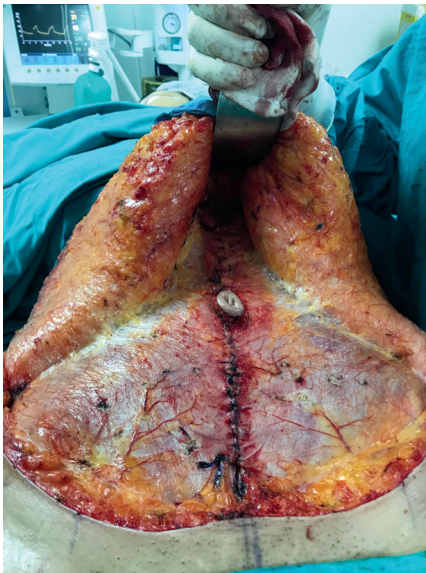

Fig. (6): A Photo show the recto-fascial plication made in two layers after dissecting and elevation of upper abdominal flap.

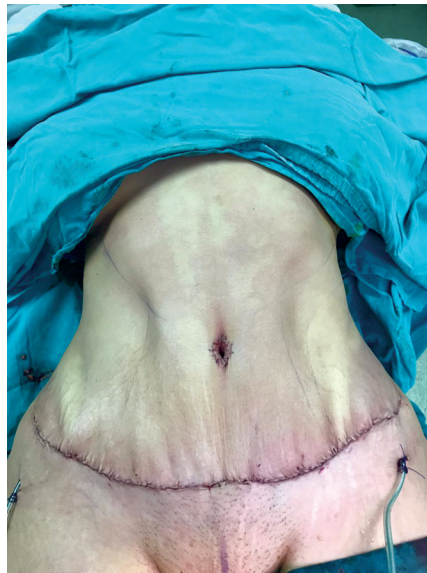

Fig. (7): A Photo show the final shape of the abdomen after closure of abdominoplasty flap, with the drain inserted.

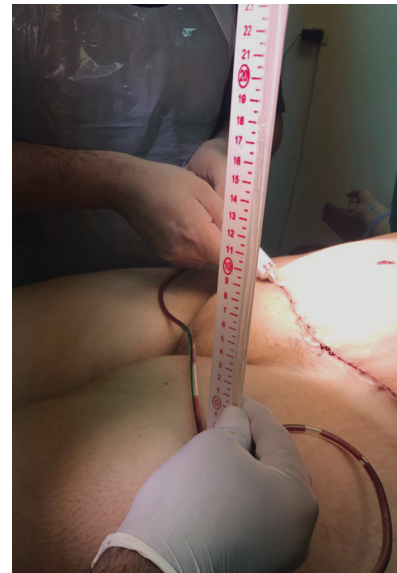

Fig. (8): A Photo show measuring the IAP after recto-fascial plication at the end of the abdominoplasty procedure.

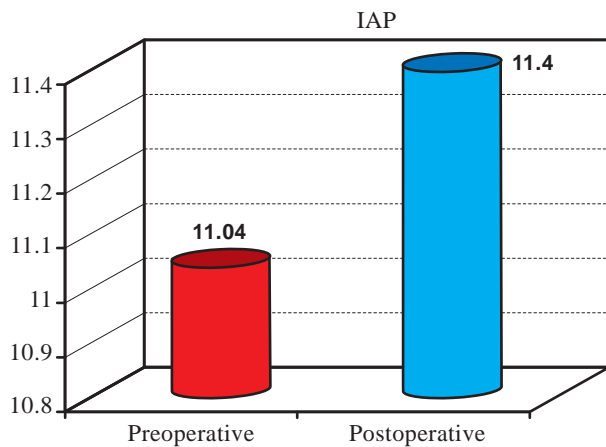


Fig. (9): A Diagram show comparison between IAP before and immediately after plication among studied patients.

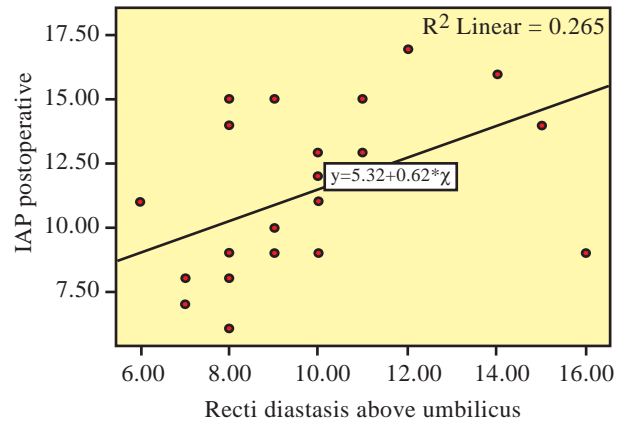


Fig. (10): A Diagram show the correlation between IAP postoperative and recti diastasis above the umbilicus among studied patients.

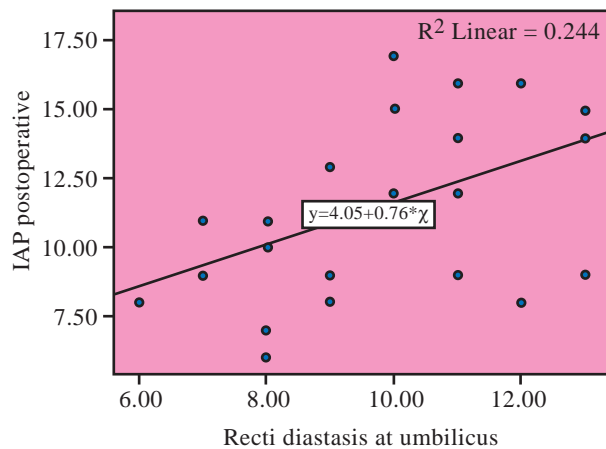


Fig. (11): A Diagram show the correlation between IAP postoperative and recti diastasis at the umbilicus among studied patients.

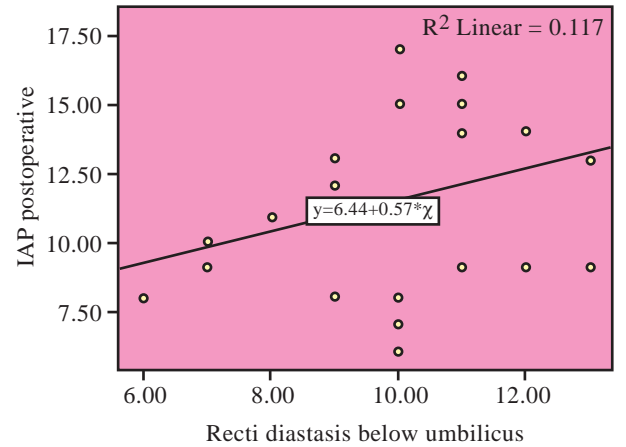


Fig. (12): A Diagram show the correlation between IAP Postoperative and recti diastases below the umbilicus among studied patients.

## DISCUSSION

Body shaping surgery, particularly abdominoplasty, considered as one of the most common surgeries nowadays. According to American Society of Plastic and Reconstructive Surgery statistics, there was a rising of 227% in the number of cases performed from 1992 to 1999 [2]. Patients presents with variety of body dysmorphism, ranging from mild lipodystrophy to significant redundancy of abdomen with or without weakness of abdominal musculature and diastasis recti. The results of the abdominal contour procedures can provide a desired "hourglass type" figure to many of the candidates [17-20]. All the patients included in the current study were good candidates for the abdominoplasty procedures, they presented with apron abdomen after massive weight loss or childbirth, with anterior abdominal wall weakness and diastasis recti, thus the procedure necessitate recto-fascial plication. All patients included are satisfied with the aesthetic results achieved from surgery.

The abdomen has a dynamic muscular wall that can accommodate a wide variation in volume with little change in intra-abdominal pressure [21]. We had assigned our study in order to evaluate the relationship between the distance of rectus plication and the intra-abdominal pressure (IAP) changes before and immediately after abdominoplasty by applying U-tube technique [13,14].

Recto-facial plication technique induces extrinsic compression on the internal abdominal contents. This induces an increase in intra-abdominal pressure (IAP). The three most reliable methods of indirectly measuring IAP are gastric, inferior vena caval, and urinary bladder pressure measurements [22]. In the current study, intra-vesicular pressure technique were used to measure the IAP because of its simplicity and accessibility in a catheterized patient.

Zhou et al., in 2010 reported that multiparous women of childbearing age (from 19 to 30 years old) who give birth vaginally with short intervals between pregnancies are more vulnerable to developing diastasis [23]. The repositioning of the rectus abdominis muscles in the midline produces an increase in IAP [24-26]. The elevated tension of the abdominal wall caused by corrected rectus diastases is not the only cause of IAP elevation. Postoperative pain, a semi-flexed posture, and the pressure exerted by the compressive garment also play an important role in the increase of the IAP [9,10,24,25].

There are few previous studies addressing IAP measurement in the context of abdominoplasty that

are available [8,11,12,24,27]. This is why, to date, the effects of plication of the rectus abdominis on IAP were only partially known. Among them a previous study by Rodrigues et al., in 2015, who studied the influence of the variation of the intra-abdominal pressure after correction of rectus diastasis. They did not reveal any relationship between the relative diastases coefficient (RDC) values and IAP variations, indicating that the size of the diastasis width is not related to a proportional increase in the IAP [8]. Another study by Pereira et al., in 2016 who studied the hemodynamic alterations during massive incisional hernioplasty, and found that no correlation had been identified between the decrease of abdominal circumference and the increase in IAP [11]. These findings are in agreement with Rodrigues et al., in 2015 findings [8]. In contrast to these previous studies, the results of our current study reports an increase of the IAP after the recto-fascial plication, and when studying the correlation between postoperative IAP and recti diastasis at the 3 different levels among studied patients statistically, results showed that positive significant correlations were present between postoperative IAP and recti diastasis at the 3 different levels, being highly significant above the umbilicus. Despite that our study reported that the postoperative IAP showed non significant increase after surgical maneuver compared to the preoperative IAP.

Previous studies such as Talisman et al., in 2002 & Helene et al., in 2006, showed that there were no relationship between the rise in IAP postoperative and the complication rate [9,25]. It was agreed by our current study, that despite the rise of IAP postoperative, but this was not related to the complication rate as it was only 2.6%.

In previous studies which conducted after 2006, which studied the changes in IAP, the IAP was measured by the same technique (U-tube technique) as we used in our current study [8,28]. However, such studies used the technique described by Kron et al., in 1984 [29], without applying the changes recommended by the International Conference [30]. This is why, to date, the effects of plication of the rectus abdominis on IAP were only partially known, and prior studies lose their validity in terms of the clinical applicability of their results.

Other trials to measure IAP in patients performing abdominoplasty include a study by Huang et al., in 2007, with a degree of flexed position in bed or the use of a binder, have been undertaken [12]. However, it revealed that in this type of inves-

tigation, intra-vesicular measurement of IAP is not a valuable technique since such a method is over-rated when introducing other variables that can affect it, such as the absence of decubitus in 0°, or of neuromuscular blockade.

Graça Neto et al., in 2006, performed analysis of postoperative IAP after Abdominoplasty, they reported complication of two cases with mild dyspnea and tachypnea [24]. In contrast to our study, which did not report any such complications related to breathing or related to intra-abdominal organs compression among our 75 patients.

Our study has some limitations, of these limitations, the relatively small number of studied patients and the limited range of diastasis distances. In addition, it is important to consider the variation in the BMI among patients. Non-obese patients have a smaller diastasis and a small volume of intra-abdominal fat. Thus, diastasis correction in these patients may results in a limited rise in the IAP in comparison to obese patients with larger diastasis and a larger amount of intra-abdominal fat.

#### Conclusion:

The restoration of the integrity of the anterior abdominal wall by abdominoplasty and muscle plication provides dynamic support and protects the abdominal contents. As a result of our current study, rectus diastasis width is significantly correlated with the IAP immediately after abdominoplasty, therefore the larger the width of the rectus diastasis, the more increase of IAP that would happen immediately after abdominoplasty.

We recommended the following in order to better understanding of the relationship between the distance of rectus plication and the intra-abdominal pressure (IAP) changes before and immediately after recto-fascial plication:

- 1- Further studies with larger sample size are needed.
- 2- Further similar study should be designed after inclusion of BMI pre and postoperative in order to avoid variation in the BMI among patients.
- 3- Further studies including patients presenting with larger diastases is needed to provide a better understanding of the treatment of this deformity.
- 4- Further similar study should focus on the hazardous effects of abdominoplasty on pulmonary functions.

#### REFERENCES

- 1- Dixit V.V. and Wagh M.S.: Unfavorable Outcomes of Liposuction and Their Management. *Indian J. of Plast. Surg.*, 46 (2): 377, 2013.
- 2- Rohrich R.J.: The American Society of Plastic Surgeons' Procedural Statistics: What They Really Mean. *Plast. and Reconst. Surg.*, 112 (5): 1389, 2003.
- 3- Verissimo P., Nahas F.X., Barbosa M.V., Gomes H.F. and Ferreira L.M.: Is it Possible to Repair Diastasis Recti and Shorten the Aponeurosis at the Same Time? *Aesthet. Plast. Surg.*, 382: 379, 2014.
- 4- Boissonault J.S. and Blaschak M.J.: Incidence of Diastasis Recti Abdominis during the Childbearing Year. *Physical Therapy*, 68 (7): 1082, 2015.
- 5- Benjamin D.R., Van de Water A.T. and Peiris C.L.: Effects of Exercise on Diastasis of The Rectus Abdominis Muscle in The Antenatal and Postnatal Periods: A Systematic Review. *Physiotherapy*, 100 (1): 1, 2014.
- 6- Thorek M.: Plastic Reconstruction of the Female Breasts and Abdomen. *The American Journal of Surgery*, 43 (2): 268, 1999.
- 7- Psillakis J.M.: Abdominoplasty: Some Ideas to Improve Results. *Aesthetic Plastic Surgery*, 2 (1): 205, 1978.
- 8- Rodrigues M.A., Nahas F.X., Reis R.P. and Ferreira L.M.: Diastasis Width Influence the Variation of the Intra-Abdominal Pressure After Correction of Rectus Diastasis? *Aesthet. Surg. J.*, 355: 583, 2015.
- 9- Talisman R., Kaplan B., Haik J., et al.: Measuring Alterations in Intra-Abdominal Pressure during Abdominoplasty As a Predictive Value For Possible Postoperative Complications. *Aesthet. Plast. Surg.*, 263: 189, 2002.
- 10- Al-Basti H.B., El-Khatib H.A., Taha A., Sattar H.A. and Bener A.: Intra-abdominal Pressure after Full Abdominoplasty in Obese Multiparous Patients. *Plast. Reconstr. Surg.*, 113: 2145, 2004.
- 11- Pereira N., Sciaraffia C., Danilla S., Parada F., Asfora C. and Moral C. Effects of Abdominoplasty on Intra-Abdominal Pressure and Pulmonary Function. *Aesthetic Surgery Journal*, 36 (6): 697, 2016.
- 12- Huang G.J., Bajaj A.K., Gupta S., et al.: Increased Intra-abdominal Pressure in Abdominoplasty: Delineation of Risk Factors. *Plast. Reconstr. Surg.*, 119: 1319, 2007.
- 13- Milanesi R. and Caregnato R.C.A.: Intra-Abdominal Pressure: An Integrative Review. *einstein*. 14 (3): 423, 2016.
- 14- Lee R.K.: Intra-Abdominal Hypertension and Abdominal Compartment Syndrome. *Critical Care Nurse*, 32 (1): 19, 2012.
- 15- Gradinger G.P., Rosenfield L.K. and Nahai F.R.: The Art of Aesthetic Surgery: Principles and Techniques. *Abdominoplasty*, Chapter 83 (3): 2<sup>nd</sup> edition: 2935, 2010.
- 16- Campbell M.J., Julious S.A. and Altman D.G.: Estimating Sample Sizes for Binary, Ordered Categorical, and Continuous Outcomes in Two Group Comparisons. *BMJ*, 311 (7013): 1145, 1995.
- 17- Baroudi R., Keppke E.M. and Netto F.T.: Abdominoplasty. *Plast. Reconstr. Surg.*, 54: 161, 1974.



- 18- Floros C. and Davis P.K.B.: Complications and Long-Term Results Following Abdominoplasty: A Retrospective Study. *Brit. J. Plast. Surg.*, 44: 190, 1991.
- 19- Hester T.R., Baird W., Bostwick III J., Nahai F. and Cukic J.: Abdominoplasty Combined with Other Major Surgical Procedures: Safe Or Sorry? *Plast. Reconst. Surg.*, 86: 997, 1989.
- 20- Al-Qattan M.M.: Abdominoplasty in Multiparous Women with Severe Musculoaponeurotic Laxity. *Brit. J. Plast. Surg.*, 50: 450, 1997.
- 21- Saggi B.H., Sugerman H.J., Ivatury R.R. and Bloomfield G.L.: Abdominal Compartment Syndrome. *J. Trauma*, 45: 597, 1998.
- 22- Pierri A., Munegato G., Carraro L., Zaccaria F., Tiso E. and Zotti E.F.: Hemodynamic Alterations during Massive Incisional Hernioplasty. *J. Am. Coll. Surg.*, 181: 299, 1995.
- 23- Zhou J.C., Xu Q.P., Pan K.H., Mao C. and Jin C.W.: Effect of Increased Intra-Abdominal Pressure and Decompressive Laparotomy on Aerated Lung Volume Distribution. *J. Zhejiang Univ. Sci. B.*, 115: 378, 2010.
- 24- Graça Neto L., Araújo L.R., Rudy M.R., Auersvald L.A. and Graf R.: Intra-Abdominal Pressure In Abdominoplasty Patients. *Aesthet Plast. Surg.*, 30: 655, 2006.
- 25- Helene A., Saad R. and Stirbulov R.: Respiratory Evaluation In Patients Submitted To Abdominoplasty. *Rev. Col. Bras Cir.*, 331: 45, 2006.
- 26- Brauman D.: Diastasis Recti: Clinical Anatomy. *Plast. Reconstr. Surg.*, 1225: 1564, 2008.
- 27- Marín J.A., Saucedo J.A., Fuentes C., et al.: Variación De La Presión Intra-abdominal Causada Por Abdominoplastía En Mujeres Sanas. *Rev. Gastroenterol. Mex.*, 69: 156, 2004.
- 28- Rodrigues M.A., Nahas F.X., Gomes H.C. and Ferreira L.M.: Ventilatory Function and Intra-Abdominal Pressure In Patients Who Underwent Abdominoplasty With Plication of the External Oblique Aponeurosis. *Aesthetic Plast Surg.*, 37: 993, 2013.
- 29- Kron I.L., Harman P.K. and Nolan S.P.: The Measurement of Intra-abdominal Pressure as a Criterion for Abdominal Exploration. *Ann. Surg.*, 199: 28, 1984.
- 30- Malbrain M.L., Cheatham M.L., Kirkpatrick A., et al.: Results From the International Conference of Experts on Intra-Abdominal Hypertension and Abdominal Compartment Syndrome. I. Definitions. *Intensive Care Med.*, 32: 1722, 2006.