

Transverse Back Flap for Closure of Lumbosacral Meningocele Defects: Is It Reliable?

RAGHDA E. TALLAL, M.D.; KHALED A. REYAD, M.D. and MINA A. ESTAWROW, M.D.

The Department of Plastic Surgery, Faculty of Medicine, Ain Shams University

ABSTRACT

Background: Meningocele is one of the most complicated congenital anomalies of CNS. The main objective of closure of such abnormalities is maintaining neural tissue function as well as avoiding recurrence and infection. Reconstruction of these defects is challenging and can be done directly or by other options such as random-based local, regional, musculocutaneous flaps and skin grafting. Perforator-based transverse back flap provide a safer rational option enables to close larger defects and at the same time permits other modalities of secondary reconstruction.

Patients and Methods: In this study, we retrospectively evaluated the reliability of transverse back flap done for 30 neonates sustained different sizes of lumbosacral (23) and sacral (7) defects following repair of meningocele. Pedicled fasciocutaneous flap based on the contralateral paralumbar perforators identified by handheld Doppler was raised and rotated to cover the defect. The flap was used to close defects' size ranged from 15 to 96cm² with an average of 45cm².

Results: 25 (83.3%) flaps passed uneventfully and healed completely without any early or late complications. Only three flaps (10%) developed congestion at their distal third, and two flaps (6.7%) developed wound dehiscence which eventually healed by secondary intention.

Conclusion: Transverse back flap provides a reliable, easy and a versatile reconstructive option for lumbosacral defects following repair of Myelomeningocele.

Key Words: Transverse back flap – Myelomeningocele – Pedicled perforator flap.

Financial Disclosure: The authors received no financial support for the research, authorship, and/or publication of this article.

INTRODUCTION

Myelomeningocele (MMC) is one of the most complicated congenital CNS defects, compatible with life. The incidence is diminishing due to prenatal screening for neural tube deformations. MMC remains a prevalent congenital defect detected in around 1 in 1000 alive newborns [1]. The lumbosacral region accounts for approximately 75% of all malformations [2]. Primary wound

reconstruction is needed since it diminishes infection rates even though it has no effect on neurological outcomes [3]. The main objective for reconstructing MMC defects is to preserve the neural tissue functions as much as possible, prevent secondary infection, and provide durable coverage. Reconstruction of these defects is challenging due to scarce tissues in infants with a high incidence of wound dehiscence [4].

Local flaps were the standard choice for reconstruction of the lumbosacral MMC defects [5]. Local flaps were designed to have proper closure of the defects with minimal postoperative morbidity. These flaps included a rotation [6], V-Y advancement [7], bilobed [8], double z-rhomboid [9], and Limberg flaps [10]. However, the use of these local random pattern flaps is limited to small size defects. In this context, perforators-based flaps were the area of research to have a well vascularized flap sustaining more advancement and cover a relatively larger defect. Hill and his colleagues in 1978 [11] introduced a perforator-based fasciocutaneous flap to the sacral defect coverage and described the lumbar perforators potential for vascularization of the skin across the midline. The study's limitations were the bulky flap, with restricted arc of rotation and required the STSG application of donor site. With the advance in use of perforators-based flaps, several studies reported their use for larger lumbosacral defects [12-15]. In this study, we evaluated the reliability of perforator-based transverse back flap in reconstruction of variable sizes of defects following repair of myelomeningocele.

PATIENTS AND METHODS

This study was conducted at Ain Shams University Hospitals after ethical and board committee approval, we performed a retrospective review of all neonatal patients who had undergone MMC repair in the period from January 2017 to October

2019. Thirty patients had a previous diagnosis of lumbosacral (23 patients) and sacral (7 patients) MMC based on antenatal ultrasound. The age of the patients ranged from 3 days to 30 days. Nineteen cases were emergency with accidental rupture of the meningeal sac while 11 cases were operated upon on an elective basis. The defect size ranged from 15 to 96cm² with an average of (45cm²). The following information was obtained retrospectively: patient demographics, characteristics of the MMC

defect including the size defect, intraoperative blood transfusion necessity, early and late complications, and follow-up (Table 1). All cases were operated by the same surgical team, with operative time ranging between 90 to 120 minutes for both the repair of the neural tube and defect coverage. Early post-operative follow-up monitored and reported flap congestion, ischemia, partial or total flap loss, wound dehiscence, infection, and average hospital stay.

Table (1): Patients' clinical data.

Case no.	Age	Gender	Defect size	Blood transfusion	Early follow-up	Late sequelae
1	21 days	M	6X5		Uneventful	
2	4 days	F	7X6		Uneventful	
3	12 days	M	5X3		Uneventful	
4	5 days	M	8X4		Uneventful	
5	8 days	M	7X7		Uneventful	
6	2 days	F	5X6		Uneventful	
7	7 days	M	10X6	+	Uneventful	
8	10 days	M	9X4		Uneventful	
9	3 days	M	11X7	+	Congested distal end	Healed 2ry intention
10	5 days	F	5X4		Uneventful	
11	14 days	M	6X7		Uneventful	
12	7 days	F	10X7	+	Uneventful	
13	30 days	F	9X5		Uneventful	
14	15 days	M	6X5		Uneventful	
15	4 days	F	5X5		Uneventful	
16	2 days	M	8X9	+	Donor site dehiscence	Healed 2ry intention
17	10 days	M	10X4		Uneventful	
18	3 days	F	12X7	+	Congested distal end with 1cm loss	Healed 2ry intention
19	7 days	M	6X7		Uneventful	
20	14 days	F	10X5	+	Uneventful	
21	3 days	F	5X7		Uneventful	
22	2 days	M	6X7		Uneventful	
23	4 days	M	7X5		Uneventful	
24	4 days	F	8X9		Uneventful	
25	5 days	M	12X8	+	Congested distal end	Healed 2ry intention
26	30 days	M	5X6		Uneventful	
27	5 days	M	10X4		Uneventful	
28	3 days	F	8X9		Donor site dehiscence	Healed 2ry intention
29	7 days	F	5X4		Uneventful	
30	10 days	M	8X6		Uneventful	

Operative technique:

While under general anesthesia, patient was placed prone with padding of all the pressure points. Intravenous prophylactic antibiotics (cefuroxime 50mg/kg every 12 hours) was administered at induction and routinely maintained for 48 hours after surgery. The surgical repair starts with meticulous repair of the neural placode, basically closed with 6-0 Prolene sutures under magnification. Then, dissection of the dura mater was carried out as wide as possible to repair the dural sac to allow free motion of the postneural placode and to prevent its adhesion to dura, trying to achieve a good cord/sac ratio as described by Pang et al., [16] the

design of the flap was based on the identification of the contralateral lumbar perforators using a handheld Doppler (power: 12 MHz). The designed transverse back flap was based on the contralateral perforators (Fig. 1).

Incision was carried out through skin reaching to the fascial overlying the muscles of the back keeping it based on the paralumbar perforators, Sutures between the fascia and the dermis were taken to avoid shearing the vessels during flap elevation. Dissection and elevation of flap were carried out from lateral to medial. Meticulous homeostasis was accomplished by the use of bipolar

cautery for small vessels. On identification of the previously marked perforators, dissection was stopped, and flap was rotated to the defect. The donor site was primarily closed after undermining

of edges. The edges of the flap were then sutured onto the edges of the defect (Fig. 2). Well-padding dressing was applied. Sutures were removed 10 days post-operative.

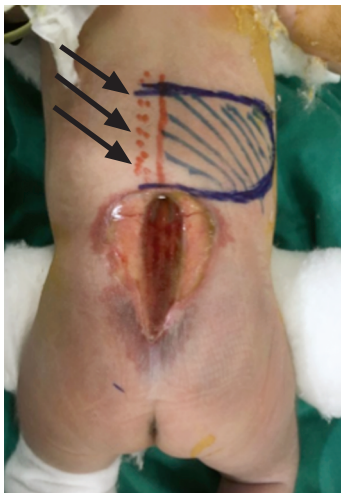


Fig. (1): Pre-operative marking of the flap after identification of contralateral lumbar perforators using handheld doppler (arrows showing the site of perforators).

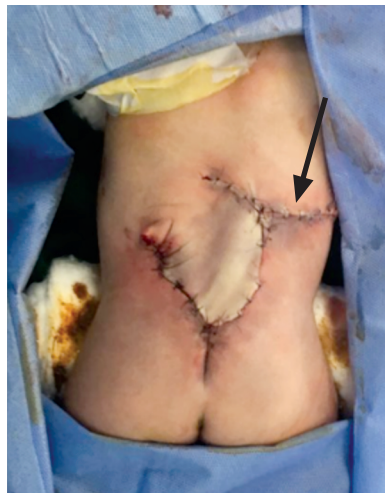

Fig. (2): The flap was dissected then rotated and sutured onto the defect with donor site closed primarily (arrow).

RESULTS

In our series, 25 flaps (83.3%) passed uneventfully and healed completely without early or late complications (Figs. 5,6,7). Three flaps (10%) developed congestion at their distal third on the third day postoperatively (Fig. 3).

Flap congestion was managed conservative which resulted in improvement of vascularity in 2 flaps on the 5th. day post-operative. One flap had partial flap necrosis with loss of the distal one cm.

however, the three flaps healed eventually by secondary intension. and they were managed by removing some sutures at the distal end of the flaps. Two flaps (6.7%) showed wound dehiscence at the junction between the flap and its donor site, and they were managed conservatively by frequent dressings. There was no flap ischemia, total flap loss or CSF leakage. Up to two years of follow-up (Fig. 4), none of the cases developed ulcers or pressure sores at the flap site, and no cases required additional surgical procedures.

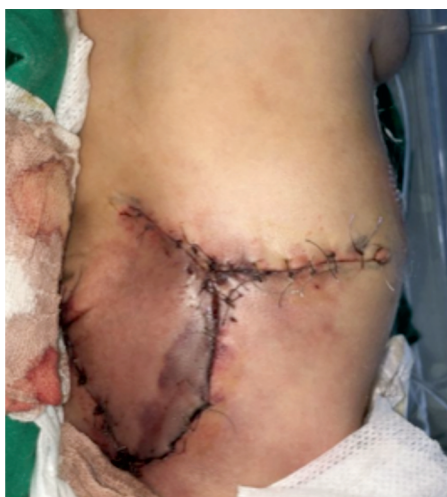

Fig. (3): Follow-up (first five days) was done for flap congestion (arrow), ischemia, partial or total flap loss, wound dehiscence and infection.

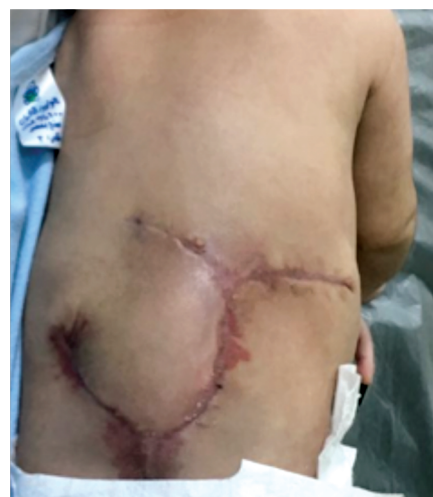

Fig. (4): Follow-up till complete healing.

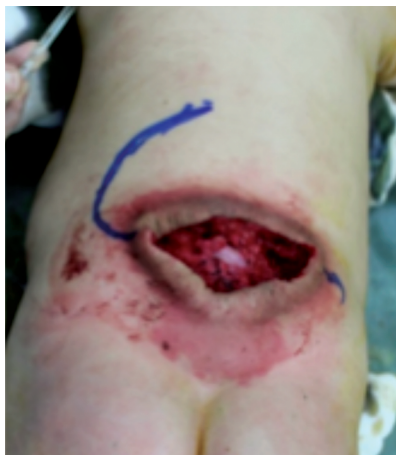

Fig. (5)

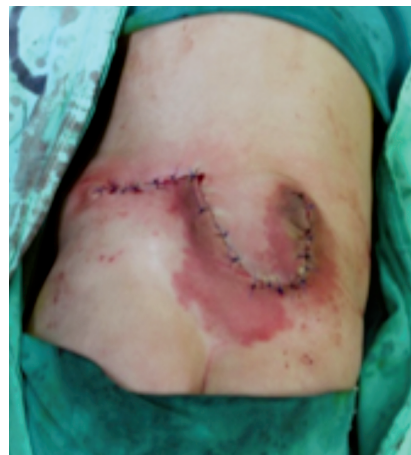

Fig. (6)

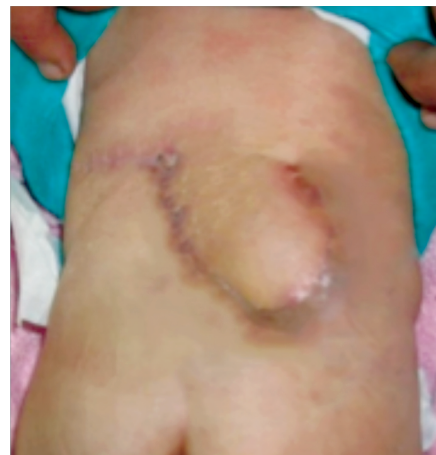

Fig. (7)

Fig. (5,6,7): Case 2: Pre-operative markings, in setting of the flap and closure of the donor site directly, follow-up till complete healing.

DISCUSSION

Myelomeningocele is a form of spina bifida. Neuronal tube formation occurs during four weeks of pregnancy when a portion of neural plates coalesce. Neural tube defects are the result of halting this process. Spina bifida is a term that refers to a failure of the posterior closure [17]. Recently, several institutions began performing fetal surgery to treat myelomeningocele, which has been demonstrated to result in ameliorated neurological function and lower morbidity [18]. Even though it is not recommended in many institutions owing to parental concerns or financial problems [19]. For these reasons, myelomeningocele postnatal closure remains the preferred choice for the repair of myelomeningocele defects.

Previous studies found that direct repair healed approximately 75% of myelomeningocele defects, whereas 25% needed alternative reconstructive choices. Large myelomeningocele defect closure is a challenge for reconstructive surgeons. The closure aims at maintaining neural tissue function and avoiding secondary infection [4]. Local flaps, skin grafting, and musculocutaneous flap variants are all reconstructive alternatives for soft tissue closure.

McCraw et al., in 1978 [20] documented the utilization of a bilateral latissimus dorsi musculocutaneous flap for myelomeningocele closure. Bilateral latissimus dorsi musculocutaneous flaps with extended gluteal fasciocutaneous flaps were also utilized [21]. Limberg latissimus dorsi musculocutaneous flaps [22], distally based latissimus dorsi flaps [23], and reverse latissimus dorsi musculocutaneous flaps [24] were also utilized to seal

myelomeningocele defects. Ramirez et al., in 1978 [25] demonstrated the usage of a combination of gluteus maximus musculocutaneous flaps and latissimus dorsi for lower sacral deformities. Local turn-over fascial flaps and midline linear skin closure for myelomeningocele defects treatment were reported by Patel et al., [26]. The perforator flap usage, including superior gluteal artery perforator flaps, dorsal intercostal artery perforator flaps as well as lumbar artery perforator flaps, have also been documented previously [27].

The utilization of local flaps is considered as a viable alternative for moderate to large lumbosacral myelomeningocele defects. Numerous distinct skin flaps, including rotation flaps [6], V-Y advancement flaps [7], double Z-rhomboid flaps [9], bilobed flaps [8], and Limberg flaps [10], have been reported. Kahn in 1965 [28] reported his use of a lumbar flap as a rotation flap to reconstruct sacral defects following pilonidal sinus surgery [28]. The transverse lumbar flap is a rationalistic option for such abnormalities since it is compatible with all lumbosacral defects, prevents midline scarring, and still provides further reconstructive alternatives [29].

Recent studies reported the potential usage of lumbar perforators to vascularize skin along the midline and even though needed skin grafting of the donor site [11-15].

In this study, we selected this flap because it offers alike by like tissue reconstruction, makes the pliability of the surrounding skin utilization anywhere from the upper back down to the gluteal area as well as it avoids midline scars with preservation of muscles in addition to the donor site

closure directly with no skin grafting. Of most flaps (25 out of 30), 83.3% survived without significant postoperative complications.

Only three cases (10%) developed flap congestion at the distal third of flaps, and two cases (6.6%) developed wound dehiscence at the junction between the flap and its donor site. These cases were managed conservatively without additional surgery and no partial or total flaps loss. This makes the transverse back flap to be considered as a good and reliable option for reconstructing lumbar and lumbosacral defects, and it should be the first option for reconstructing such defects based on its reliability, low morbidity of the donor site, and preservation of muscle for the possibility of later reconstruction in cases of recurrence or pressure ulceration.

Conclusion:

Meningocele defects are complex and challenging in reconstruction. They are prone to recurrence and need a well-vascularized, reliable, and durable soft tissue coverage. The transverse back flap provides a good option for reliable, simple, and durable coverage. It should be considered a reliable alternative for reconstructing such complicated abnormalities.

REFERENCES

- 1- Blencowe H., Kancherla V., Moorthie S., Darlison M.W. and Modell B.: Estimates of global and regional prevalence of neural tube defects for 2015: A systematic analysis. *Annals of the New York Academy of Sciences*. 10.1111/nyas.13548, 2018.
- 2- Blackburn S: maternal, fetal and neonatal physiology: A clinical perspective (5th edition) Elsevier, 2018.
- 3- Greenberg M.: *Handbook of Neurosurgery*. New York: Thieme, pp. 114-116, 2010.
- 4- El-Khatib H.A.: Large thoracolumbar meningocele defects: Incidence and clinical experiences with different modalities of latissimus dorsi musculocutaneous flap. *Br. J. Plast. Surg.*, 57: 411-417, 2004.
- 5- Muskett A., Barber W.H., Parent A.D., et al.: Contemporary postnatal plastic surgical management of meningocele. *J. Plastic Reconstructive Aesthetic Surg.*, 65: pp. 572-577, 2012.
- 6- Highton L., Walkden J., Thorne J. and Davenport P.J.: Purse-string closure of large myelomeningoceles. *J. Plast. Reconstr. Aesthet. Surg.*, 64: e287-e288, 2011.
- 7- Ulusoy M.G: Closure of Meningomyelocele Defects with Bilateral Modified V-Y Advancement Flaps: *Annals of Plastic Surgery*, 54 (6): 640-4, July 2005.
- 8- Lapid O., Rosenberg L. and Cohen A.: Meningomyelocele reconstruction with bilobed flaps. *Br. J. Plastic Surg.*, 54: 570-2, 2001.
- 9- Cruz N.I., Ariyan S., Duncan C.C., et al.: Repair of lumbosacral myelomeningoceles with double Z-rhomboid flaps. *Technical note. J. Neurosurg.*, 59: 714-7, 1983.
- 10- Jung Hwan Shim, et al.: Closure of Myelomeningocele Defects Using a Limberg Flap or Direct Repair; *Arch. Plast. Surg.*, 43 (1): 26-31, Jan., 2016.
- 11- Hill H.L., Brown R.G. and Jurkiewicz M.J.: The transverse lumbosacral back flap. *Plastic Reconstructive Surg.*, 62: 177e84, 1978.
- 12- Donaldson C., Murday H.K.M., Gutman M.J., Maher R., Goldschlager T., Xenos C. and Danks R.A.: Long-term follow-up for keystone design perforator island flap for closure of myelomeningocele. *Childs Nerv. Syst.*, 34 (4): 733-736, Apr. 2018.
- 13- Formentin C., de Andrade E.J., Matias L.G., Joaquim A.F., Tedeschi H., Raposo-Amaral C.E. and Ghizoni E.: Using the keystone design perforator island flap in large myelomeningocele closure. *Neurosurg Focus*, 1; 47 (4): E19, Oct. 2019.
- 14- Park H.S., Morrison E., Lo C. and Leong J.: An Application of Keystone Perforator Island Flap for Closure of Lumbosacral Myelomeningocele Defects. *Ann. Plastic Surg.*, 77 (3): 332-6, Sep. 2016.
- 15- Bhagwat S. Mathur, Shaun S. Tan, F.A. Bhat and Warren Matthew Rozen: The transverse lumbar perforator flap: An anatomic and clinical study. *Journal of Plastic, Reconstructive & Aesthetic Surgery*, 69: 770e776, 2016.
- 16- Pang D., Zovickian J. and Oviedo A.: Long term outcome of total resection of spinal cord lipomas and radical reconstruction of the neural placode: Part I-surgical technique. *Neurosurgery*, 65: 511-529, 2009.
- 17- Wallingford J.B.: Neural tube closure and neural tube defects: studies in animal models reveal known knowns and known unknowns. *Am. J. Med. Genet C Semin Med. Genet*, 135C: 59-68, 2005.
- 18- Adzick N.S.: Fetal surgery for spina bifida: Past, present, future. *Semin Pediatric Surg.*, 22: 10-7, 2013.
- 19- Muskett A., Barber W.H., Parent A.D., et al.: Contemporary postnatal plastic surgical management of meningocele. *J. Plast. Reconstr. Aesthet. Surg.*, 65: 572-7, 2012.
- 20- McCraw J.B., Penix J.O. and Baker J.W.: Repair of major defects of the chest wall and spine with the latissimus dorsi myocutaneous flap. *Plastic Reconstructive Surg.*, 62: 197-206, 1978.
- 21- McDevitt N.B., Gillespie R.P., Woosley R.E., et al.: Closure of thoracic and lumbar dysraphic defects using bilateral latissimus dorsi myocutaneous flap transfer with extended gluteal fasciocutaneous flaps. *Childs Brain*, 9: 394-9, 1982.
- 22- Munro I.R., Neu B.R., Humphreys R.P., et al.: Limberg-latissimus dorsi myocutaneous flap for closure of myelomeningocele. *Childs Brain*, 10: 381-6, 1983.
- 23- Schefflan M., Mehrhof A.I. Jr., Ward J.D.: Meningomyelocele closure with distally based latissimus dorsi flap. *Plastic Reconstr. Surg.*, 73: 956-9, 1984.
- 24- VanderKolk C.A., Adson M.H. and Stevenson T.R.: The reverse latissimus dorsi muscle flap for closure of meningocele. *Plastic Reconstructive Surg.*, 81: 454-6, 1988.

- 25- Ramirez O.M., Ramasastry S.S., Granick M.S., Pang D. and Futrell J.W.: A new surgical approach to closure of large lumbosacral meningomyelocele defects. *Plastic Reconstructive Surg.*, 80: 799-809, 1987.
- 26- Patel K.B., Taghinia A.H., Proctor M.R., et al.: Extradural myelo-meningocele reconstruction using local turnover fascial flaps and midline linear skin closure. *J. Plastic Reconstructive Aesthetic Surg.*, 65: 1569-72, 2012.
- 27- El-Sabbagh A.H. and Zidan A.S.: Closure of large myelomeningocele by lumbar artery perforator flaps. *J. Reconstr Microsurg.*, 27: 287-94, 2011.
- 28- Kahn S.: Closure of recurrent or persistent sacrococcygeal pilonidal wounds with a rotated lumbar flap. *Am. J. Surg.*, 110: 996e1000, 1965.
- 29- Wong C.H., Tan B.K. and Song C.: The perforator-sparing buttock rotation flap for coverage of pressure sores. *Plastic Reconstructive Surg.*, 119: 1259e66, 2007.